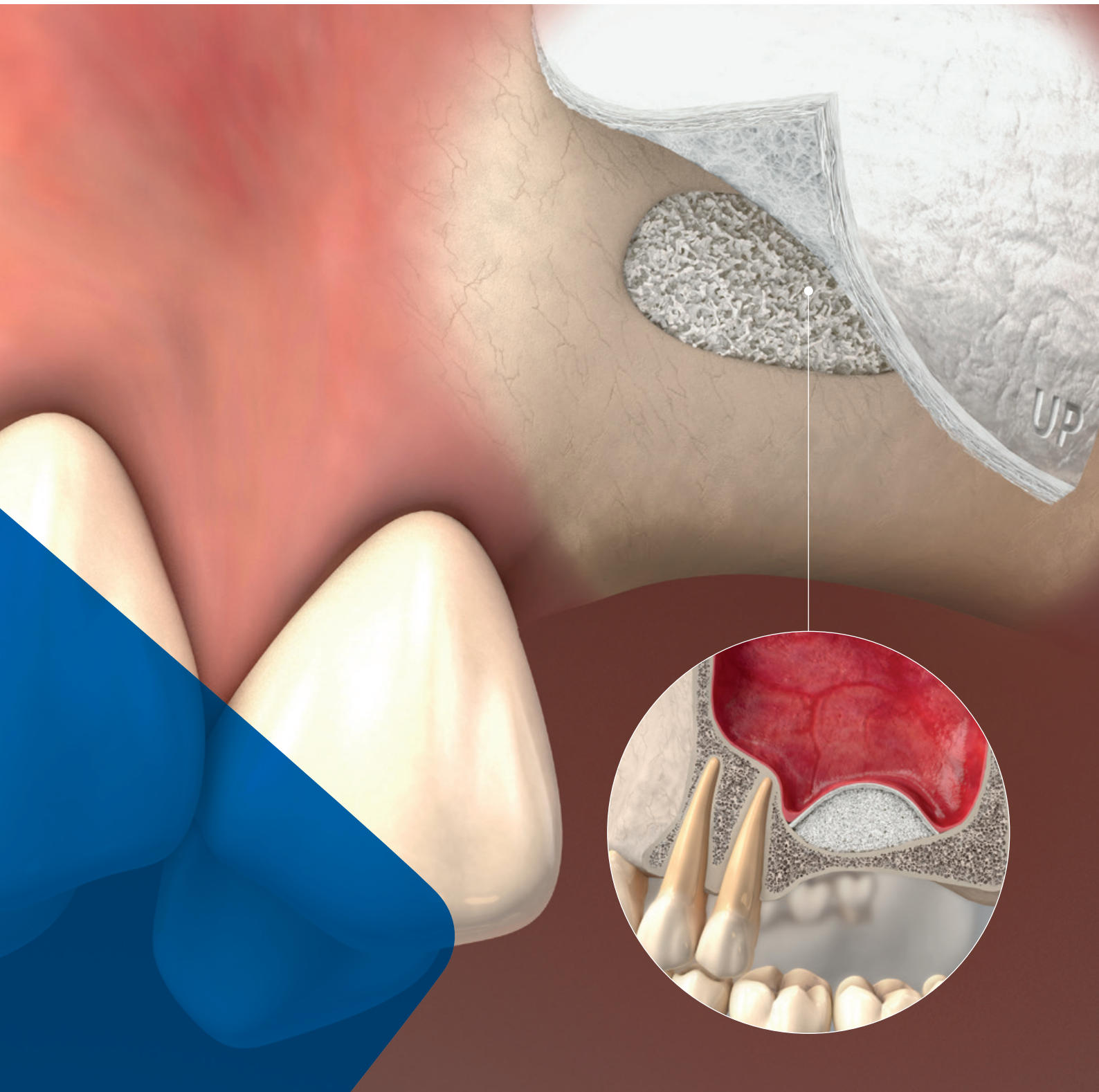



LEADING REGENERATION

Geistlich
Biomaterials

Sinus Floor Elevation

Treatment Concepts





„Geistlich Family supports your way to regeneration – together for more satisfied patients”

Dr. Andreas Geistlich

CONTENTS

- 3 Maxillary sinus floor augmentation
- 4–5 Classical treatment options and important aspects in maxillary sinus at a glance
- 6–13 **Clinical Cases: Lateral Sinus Floor Elevation**
Assoc. Prof. Stephen Wallace, USA
Prof. Angelo Menuci Neto, Brazil
Prof. Yong-Dae Kwon, South Korea
Assoc. Prof. Prisana Pripatnanont, Thailand
- 14–15 Treatment Options Maxillary Sinus Area
- 16–17 **Clinical Case: Crestal Sinus Floor Elevation**
Dr. Feng Bo, China
- 18–23 **Clinical Cases: Sinus Floor Elevation and Bone Augmentation**
Dr. Devorah Schwartz-Arad, Israel
Dr. Mehdi Merabet, France
Dr. Joao Batista César Neto, Brazil
- 24–25 **Clinical Case: Prevention of Sinus Floor Elevation**
Dr. Ryan SB Lee, Australia
- 26 Recommended Material Combinations
References
- 27 Product Range

See all clinical cases online here



Maxillary sinus floor augmentation

Continued bone loss following tooth extraction, bone atrophy and the proximity of the maxillary sinus to the site of implant placement are major challenges in implant dentistry. To overcome this issue Hilt Tatum pioneered the surgical methodology for maxillary sinus augmentation, which was published by Philip Boyne in 1980.¹ Particulated cancellous bone and marrow harvested from the lateral iliac crest was used as bone replacement material and autogenous bone became the “gold standard” bone replacement material. However, in 1996 Wheeler et al. demonstrated that the use of hydroxyapatite alone or in combination with autogenous bone leads to similar morphometric results (16.4% and 19.3% bone volume respectively).² The elimination of a second surgical site for extra-oral bone harvesting, allowed the surgical procedure to be performed at the dental office, making it easier to tolerate for patients.

Sinus floor elevation

Bone resorption (with increasing age or after the loss of a premolar or molar) and secondary pneumatization of the sinus due to the reduced functional forces on the bone after tooth extraction frequently leave insufficient residual bone height for successful implant placement.³ Sinus floor elevation procedures allow residual bone augmentation using bone replacement material to increase bone volume and quality.

By the transcrestal osteotome (Summers technique⁴) or lateral antrostomy (lateral window, pioneered by Tatum⁵) approach, a mucoperiosteal pocket is formed over the maxillary floor, a bony access to the Schneiderian membrane is achieved, beneath the Schneiderian membrane, which is subsequently filled with the bone replacement material (e.g. Geistlich Bio-Oss®) and covered with a native bilayer collagen membrane (e.g. Geistlich Bio-Gide®). The most common complication during sinus floor elevation procedures is perforation of the Schneiderian membrane. Covering the perforation with a native bilayer collagen membrane (e.g. Geistlich Bio-Gide®) serves as protection during the surgical procedure and post-operative healing.⁶

The initially remaining residual bone height determines the surgical approach for sinus augmentation and the choice between immediate or delayed implant placement. The recommendations issued by the Sinus Consensus Conference in 1996 are based on the vertical dimension of the residual bone between the alveolar crest and the maxillary sinus floor (Table 1).⁷

Sinus elevation procedures can also be implemented for single implant-supported restorations. Using Geistlich Bio-Oss® in combination with autogenous bone material covered with Geistlich Bio-Gide® both lateral antrostomy (1- and 2-stage procedure) and the osteotome technique have been associated with 100% implant survival after a follow-up of at least two years (44.5 ± 22.7 months).⁶



Residual bone height	Recommended procedure
>10 mm (class A)	> Classical implant procedure <div> <div>Extraction Socket Management</div>  <div>See “Treatment Concepts for Extraction Sockets”</div> </div> <div> <div>Minor Bone Augmentation</div>  <div>See “Treatment Concepts for Minor Bone Augmentation”</div> </div>
7–9 mm (class B)	> Osteotome technique > Immediate implant placement
4–6 mm (class C)	> Lateral antrostomy > Bone replacement material > Immediate or delayed implant placement
1–3 mm (class D)	> Lateral antrostomy > Bone replacement material > Delayed implant placement
General remark	Immediate implant placement is not recommended with residual bone height <4mm or poor bone quality

Table 1: Recommended procedure depending on residual bone height. Sinus Conference Consensus 1996.⁷

Sinus floor elevation vs. ridge preservation

Sinus floor elevation is a complex surgical procedure, which causes severe discomfort for the patient. As an alternative, ridge preservation directly after tooth extraction is a minimally invasive approach, which allows preservation of >90% of bone volume in the posterior region and bone regeneration within 6 months.⁸ Following ridge preservation, standard implant placement can usually be performed without the need for additional bone augmentation.⁹

Short implants

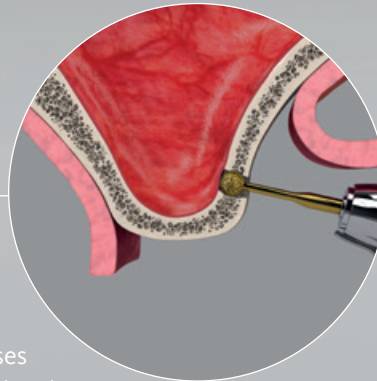
Adequate bone quality and volume are prerequisites for successful implant placement and long-term stability.^{10,11} Implant length needs to be carefully selected in relation to the anatomical situation. Even though long implants are considered the best option, their use may not always be possible. In these cases, short implants (<10 mm) are a valid alternative. Advances in surface geometry and texture have increased the bone-implant contact area, leading to improved primary stability and long-term osseointegration.¹²

However, short implants have certain limitations, such as an unfavorable crown-to-implant ratio, poor aesthetics in the anterior atrophic maxilla and difficult plaque control. In addition, in cases with marginal bone loss, the risk of implant failure is increased due to reduced bone to implant contact.¹³

Classical treatment options and important aspects in maxillary sinus at a glance

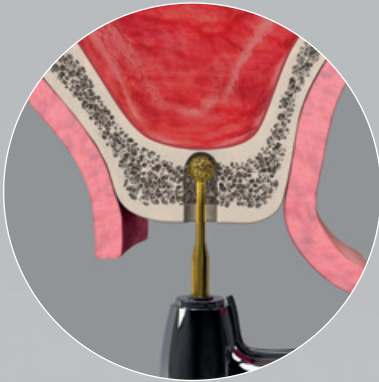
Lateral antrostomy (lateral window) technique¹⁴

- > Well-documented and reliable procedure
- > Implant survival rates of 61.2%–100%
- > Perforation of the Schneiderian membrane occurs in 10%–20% of cases
- > Immediate or delayed implant placement depending on residual bone height



Transcrestal osteome technique¹⁴

- > Can be used for wide ridge and relatively flat anatomy
- > Requires initial residual bone height ≥ 5 mm
- > Immediate implant placement
- > Perforation of the Schneiderian membrane can be difficult to manage



Geistlich Bio-Oss® and Geistlich Bio-Gide® – long-term success with the Dream-Team

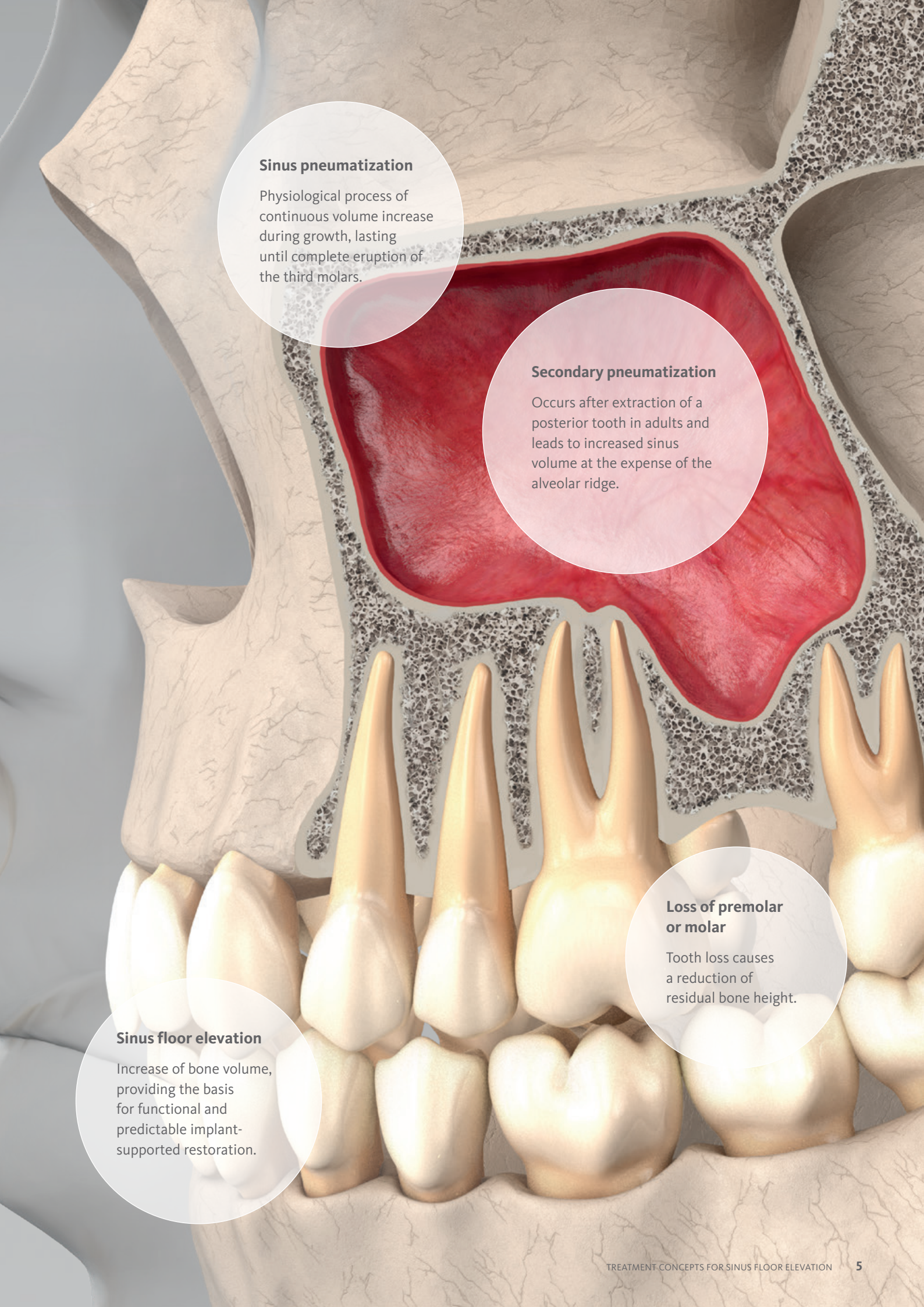
Geistlich Bio-Oss® and Geistlich Bio-Gide® are the leading bone substitute and barrier membrane in regenerative dentistry.^{15,16,34–38}

Geistlich Bio-Oss® in sinus floor augmentation:

- > Allows effective and predictable bone regeneration.^{17–19}
- > Contributes to long-term stability and maintenance of bone volume (follow-up 10 years), due to its slow resorption.¹⁹
- > Use as only augmentation material, leads to a 98.2% implant survival rate (follow-up 3 years).²⁰
- > Makes the inclusion of autologous bone unnecessary.²⁰
- > Available in two granule sizes (0.25–1 mm and 1–2 mm), which both lead to excellent clinical and histomorphometric performance.²¹

Geistlich Bio-Gide® as protection of the grafted area:

- > Significantly increases newly formed bone compared to procedures without membrane coverage (various graft materials).²²
- > Increases implant survival rate by 5% to reach up to 98.6% (grafting material Geistlich Bio-Oss®).²³
- > Serves as protection during the surgical procedure and post-operative healing.⁶



The diagram illustrates the anatomical changes in the maxilla. The maxillary sinus is shown in red, with its floor elevated. The alveolar ridge is shown in grey, with a reduction in height. The teeth are shown in yellow, with a reduction in height. The text boxes provide detailed information about these changes.

Sinus pneumatization

Physiological process of continuous volume increase during growth, lasting until complete eruption of the third molars.

Secondary pneumatization

Occurs after extraction of a posterior tooth in adults and leads to increased sinus volume at the expense of the alveolar ridge.

Loss of premolar or molar

Tooth loss causes a reduction of residual bone height.

Sinus floor elevation

Increase of bone volume, providing the basis for functional and predictable implant-supported restoration.

Lateral Sinus Elevation with 13-year follow-up



Assoc. Prof. Stephen Wallace | New York, USA

CLINICAL CHALLENGE

A 63-year-old female patient presents with hopeless maxillary teeth and a desire for a fixed reconstruction. A staged case was planned with the canines used as abutments for a fixed provisional while sinus augmentation and delayed implant placement were being accomplished. The case presented with 1–2mm of crestal bone in the molar sites. During sinus augmentation surgery the thin Schneiderian membrane on the right side was extensively torn. A collagen membrane repair procedure was performed and bilateral sinus augmentations were completed with Geistlich Bio-Oss® as the sole grafting material covering the lateral window with a Geistlich Bio-Gide® membrane. After an extended delay (financial) implants were placed in the grafted sinuses and a bone core

harvested through the lateral window. The anterior teeth were extracted and the provisional was extended to the posterior implants. Implants were later placed in the canine sites and the final prosthesis was fabricated. The final follow-up is 13 years on from the sinus augmentation.

AIM/APPROACH

- There are 3 interesting challenges in this case:
1. Sinus augmentations performed with 100% Geistlich Bio-Oss® when only 1–2mm of crestal bone remains
 2. Achieving a successful result in the face of an extensive perforation
 3. Assuming some loss of the existing crestal bone due to biologic width formation, the molar implants have existed with Geistlich Bio-Oss® likely at the crest for close to 10 years.

CONCLUSION

- › Cases with severe pneumatization can be grafted with Geistlich Bio-Oss® as the sole grafting material.
- › Geistlich Bio-Oss® alone, covered with a Geistlich Bio-Gide® membrane can give successful results in compromised clinical situations. Histomorphometric evaluation showed 31% vital bone with all implants successful by any guidelines.
- › Having Geistlich Bio-Oss® exposed at the crest did not result in periimplantitis.

Clinical outcome at a glance

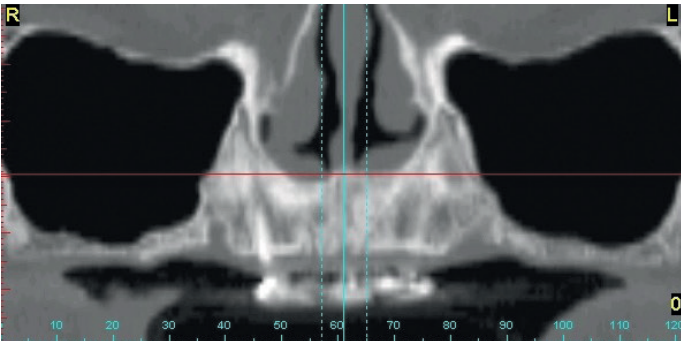
OBJECTIVES

- › Staged sinus floor elevation with 100% Geistlich Bio-Oss® and Geistlich Bio-Gide® when only 1–2mm crestal bone remains.
- › Fixed maxillary reconstruction on both sides.
- › Successful implant placement 1-year after sinus floor elevation.

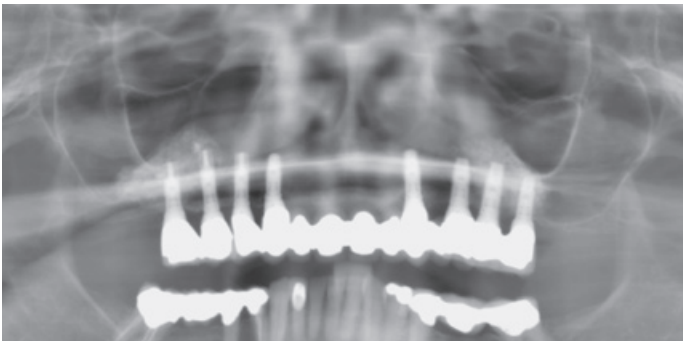
CONCLUSIONS

- › Two-stage sinus floor elevation treatment.
- › Successful sinus floor elevation of severe pneumatization with Geistlich Bio-Oss® and Geistlich Bio-Gide® shows stable bony volume after 13-year follow-up.

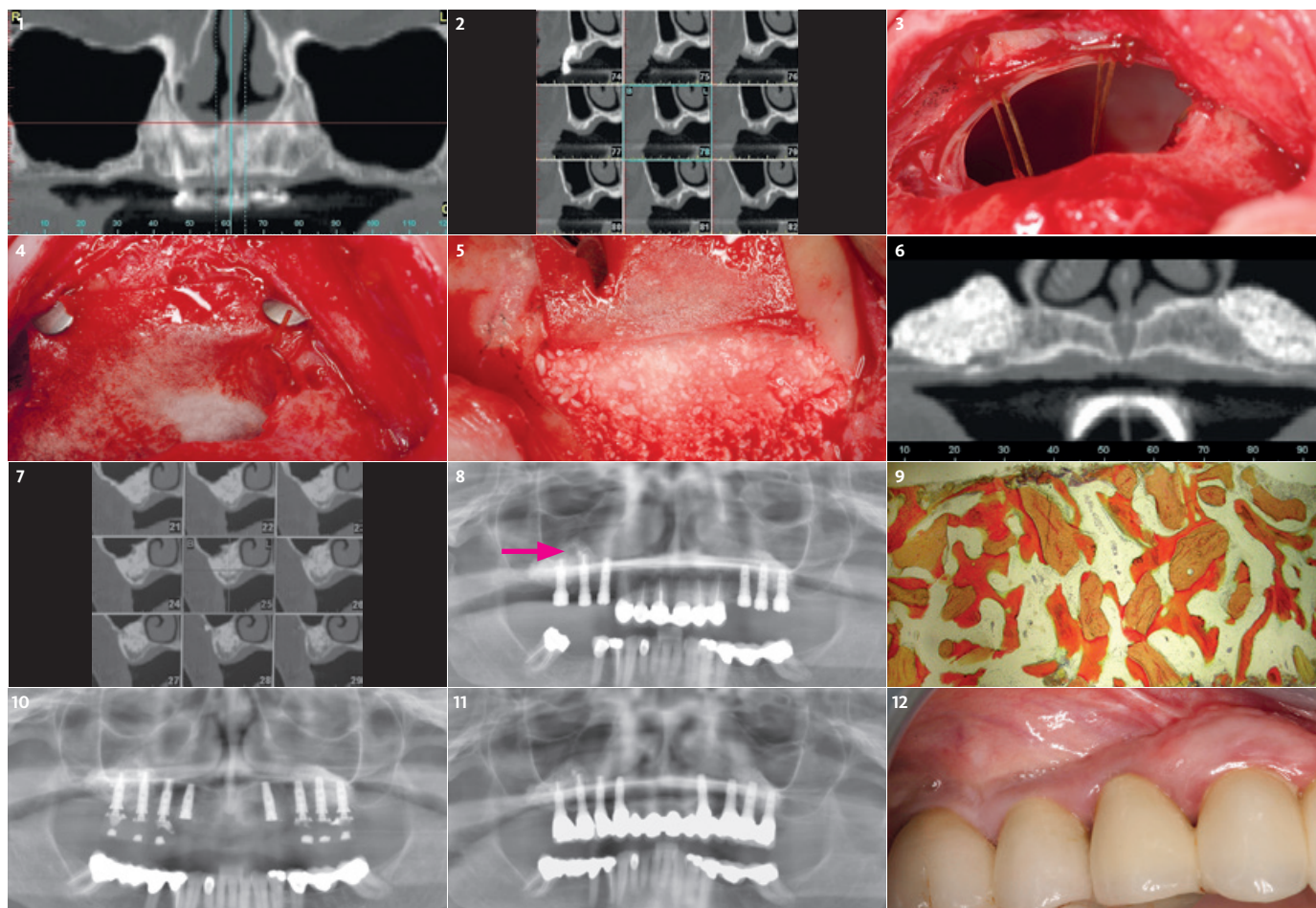
BEFORE



AFTER



APPROACH	TREATMENT	ADDITIONAL MEANS
<input checked="" type="checkbox"/> Lateral	<input checked="" type="checkbox"/> Geistlich Bio-Oss®	<input type="checkbox"/> One-stage
<input type="checkbox"/> Crestal	<input checked="" type="checkbox"/> Geistlich Bio-Gide®	<input checked="" type="checkbox"/> Two-stage
<input type="checkbox"/> Bone Regeneration		



1 Preoperative panoramic radiological view after posterior tooth extraction.

2 Preoperative paraxial radiological view of the right sinus showing limited crestal bone of 1–2 mm.

3 Intraoperative view of the right sinus showing extensive perforation and the beginning of repair with suture "struts".

4 Completion of repair with a collagen membrane and bone tacks.

5 Sinus floor augmentation with Geistlich Bio-Oss® prior to placing Geistlich Bio-Gide® membrane to cover the lateral window.

6 1 year postoperative panoramic radiological picture showing both augmented areas.

7 1 year paraxial radiological picture of the right sinus showing excellent graft containment.

8 Bone core was taken between the distal implants on the right side (red arrow) prior to the radiological picture of implant placement after 1-year sinus floor elevation.

9 Histological picture of the harvested bone core showing 31% newly formed bone (dark orange). 25% Geistlich Bio-Oss® particles (light orange) and 44% bone marrow.

10 Postoperative radiological situation after 1.5 years. Anterior teeth removed, canine fixtures placed and provisional is on sinus fixtures.

11 Radiological picture showing final prosthesis in place at 10 years.

12 Clinical view of the final prosthesis after 13 years – right side.

Lateral sinus floor elevation with a bony fenestration of the sinus floor



Prof. Angelo Menuci Neto, MSC, DDS & Prof. Washington Santana, PHD. MSC | Porto Alegre & Goiania, Brazil

CLINICAL CHALLENGE

The patient described here is a 56-year old non-smoker and in good general health. She reported a history of dental extraction in right side of the posterior maxillary region about 3 months earlier. The treatment plan envisages a fixed prosthetic restoration, and to achieve this goal, a surgical procedure of sinus augmentation prior to implant placement was performed.

AIM/APPROACH

A full-thickness flap was raised to expose the lateral wall of the sinus. After osteotomy was performed, the sinus membrane was carefully elevated and space was created for the bone graft under the sinus membrane. Then a cut out part of Geistlich Bio-Gide® was used to obliterate the fenestration in the lower osseous wall of the sinus. The grafting material Geistlich Bio-Oss® was gently packed into the sinus cavity, followed by placement of Geistlich Bio-Gide® shaped and positioned to cover the antrostomy window. After 8 months, a dental implant was inserted into the grafted site. The prosthetic rehabilitation was performed 4 months after installing the implant.

CONCLUSION

This clinical case, with 12-month follow-up, showed the employment of Geistlich Bio-Oss® and Geistlich Bio-Gide® in sinus floor elevation for the purpose of rehabilitation with dental implants. The good prosthetic result achieved confirms the excellent osteoconductive properties for osseointegration.

Clinical outcome at a glance

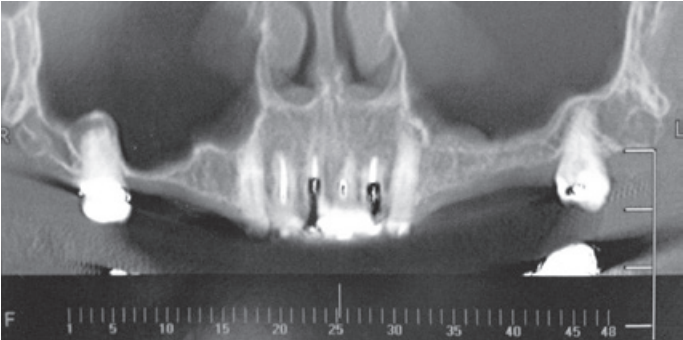
OBJECTIVES

- > Sinus floor elevation with lateral window approach.
- > Fixed prosthetic restoration in the posterior maxilla.
- > Sinus floor elevation prior to implant placement.

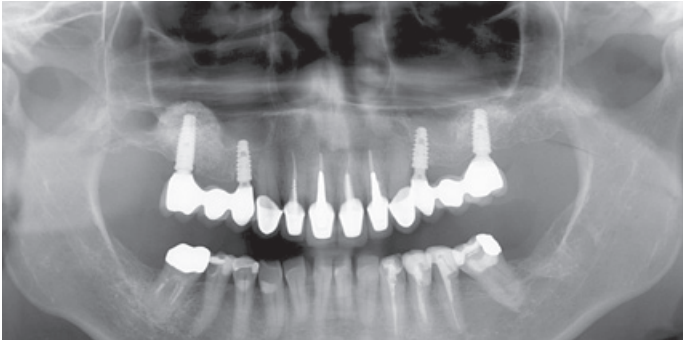
CONCLUSIONS

- > Two-stage sinus floor elevation treatment.
- > This clinical case shows excellent osteoconductive behavior of Geistlich Bio-Oss® and uneventful healing of Geistlich Bio-Gide®.
- > Good prosthetic results due to excellent osseointegration of the implant in the augmented site.

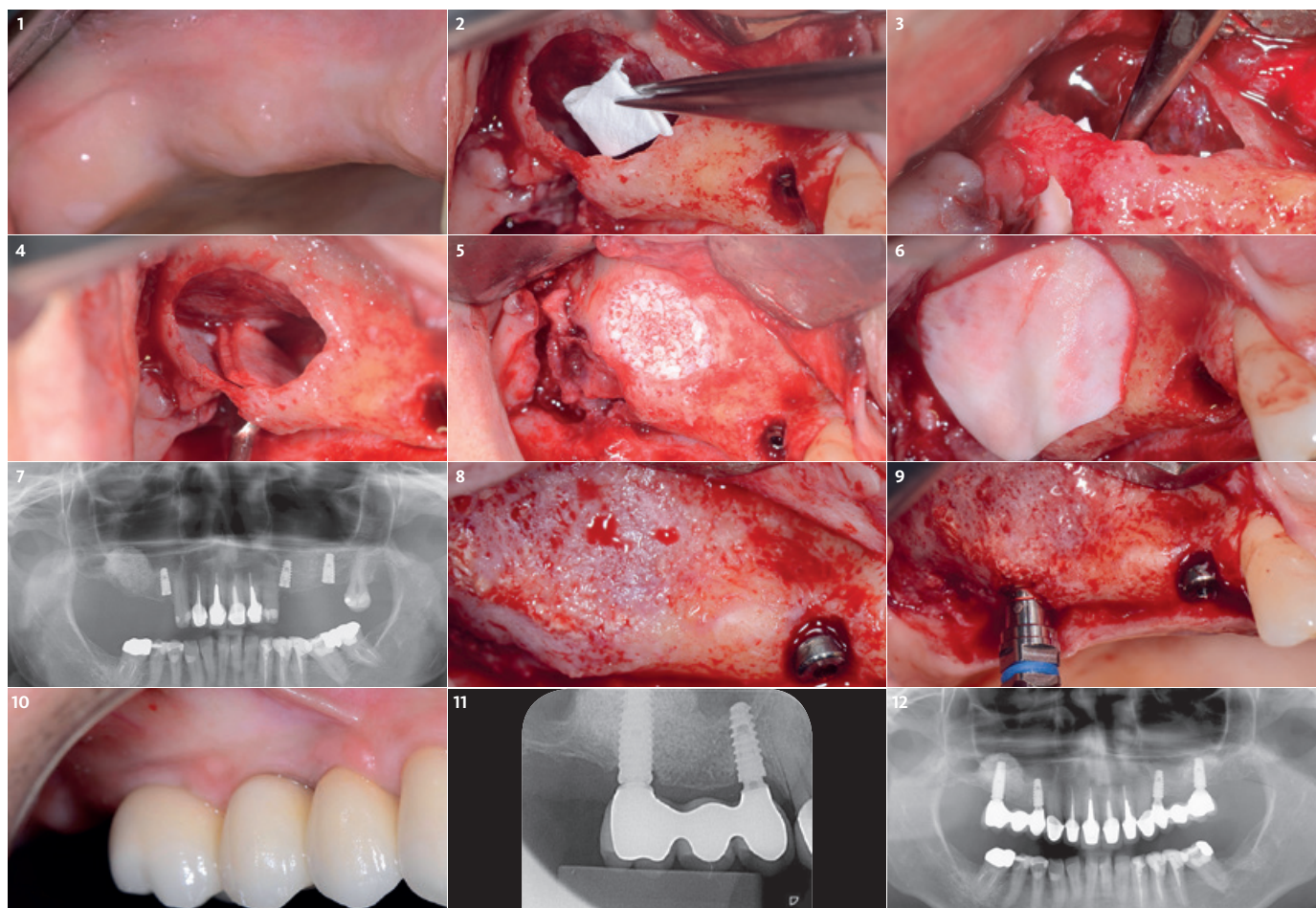
BEFORE



AFTER



APPROACH	TREATMENT	ADDITIONAL MEANS
<input checked="" type="checkbox"/> Lateral	<input checked="" type="checkbox"/> Geistlich Bio-Oss®	<input type="checkbox"/> One-stage
<input type="checkbox"/> Crestal	<input checked="" type="checkbox"/> Geistlich Bio-Gide®	<input checked="" type="checkbox"/> Two-stage
<input type="checkbox"/> Bone Regeneration		



1 Preoperative picture of the area intended to be treated.

2 Application of the Geistlich Bio-Gide® to seal bone fenestration in sinus floor.

3 Covering bony defect on the sinus floor with Geistlich Bio-Gide®.

4 Closing bony defect on the sinus floor with Geistlich Bio-Gide® before filling the sinus floor cavity.

5 Sinus floor augmentation using Geistlich Bio-Oss®.

6 Lateral window to the sinus cavity is covered with Geistlich Bio-Gide®.

7 Panoramic radiography view after a follow-up time of 8 months prior to reentry and implant placement.

8 Clinical situation and bone volume at the augmented site after 8 months.

9 Implant placement at the augmented sinus floor.

10 4 months after implant placement the final restoration was performed with a three-unit bridge prosthesis (Dr. Álvaro Martins/ Goiânia, Brazil).

11 Final periapical radiography after 12 months.

12 12-month follow-up panoramic radiography.

Lateral sinus floor elevation in the presence of an antral pseudocyst and simultaneous implant placement



Prof. Yong-Dae Kwon | Seoul, South Korea

CLINICAL CHALLENGE

A middle-aged male came to the clinic for dental implant placement. The panoramic radiography showed a hazy shadow in the right maxillary sinus. A CBCT scan was taken for further evaluation and revealed a dome-shaped radiopacity. The radiographic impression was an antral pseudocyst. In the region of the 1st molar the residual bone height was enough to avoid a lateral window approach. But the morphology of the residual ridge in the 1st molar area and the presence of an antral pseudocyst were not favorable indicators for a transcrestal sinus floor elevation.

AIM/APPROACH

In order to ensure that the radiopacity would be nothing but a non-symptomatic antral pseudocyst, sinus floor elevation via the lateral window technique was planned. After opening up a bony window, I was able to aspirate the small cystic lesion with yellowish mucus. During the procedure, a perforation was found and successfully repaired with a Geistlich Bio-Gide®.

CONCLUSION

Geistlich Bio-Gide® is because of its easy manipulation and its good adhesion to the Schneiderian membrane a great product for the perforation repair and should be properly trimmed and placed to ensure it spreads sufficiently to completely cover the perforation.

Clinical outcome at a glance

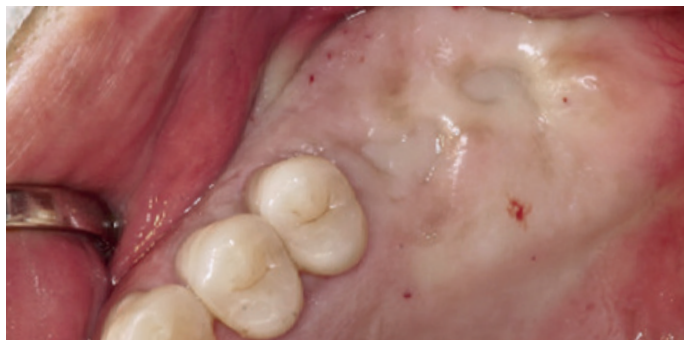OBJECTIVES

- > Lateral sinus floor elevation using Geistlich Bio-Oss Pen® and Geistlich Bio-Gide®.
- > Augmentation is simultaneous with implant placement in sites 16 and 17.
- > Aspiration of a small cystic lesion in the sinus cavity.

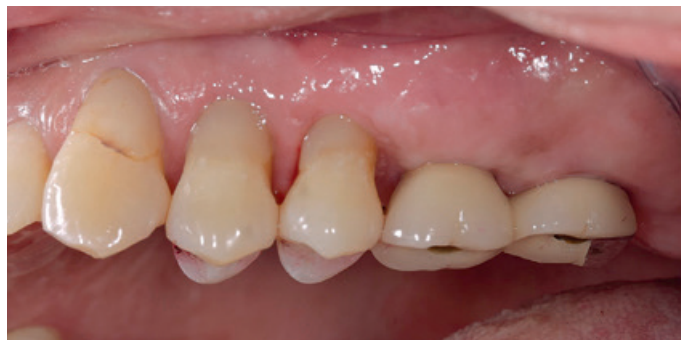CONCLUSIONS

- > One-stage sinus floor elevation treatment.
- > Very promising clinical outcome with the use of Geistlich Bio-Oss Pen® and Geistlich Bio-Gide®.
- > Geistlich Bio-Gide® is very suitable for repairing a perforated Schneiderian membrane.

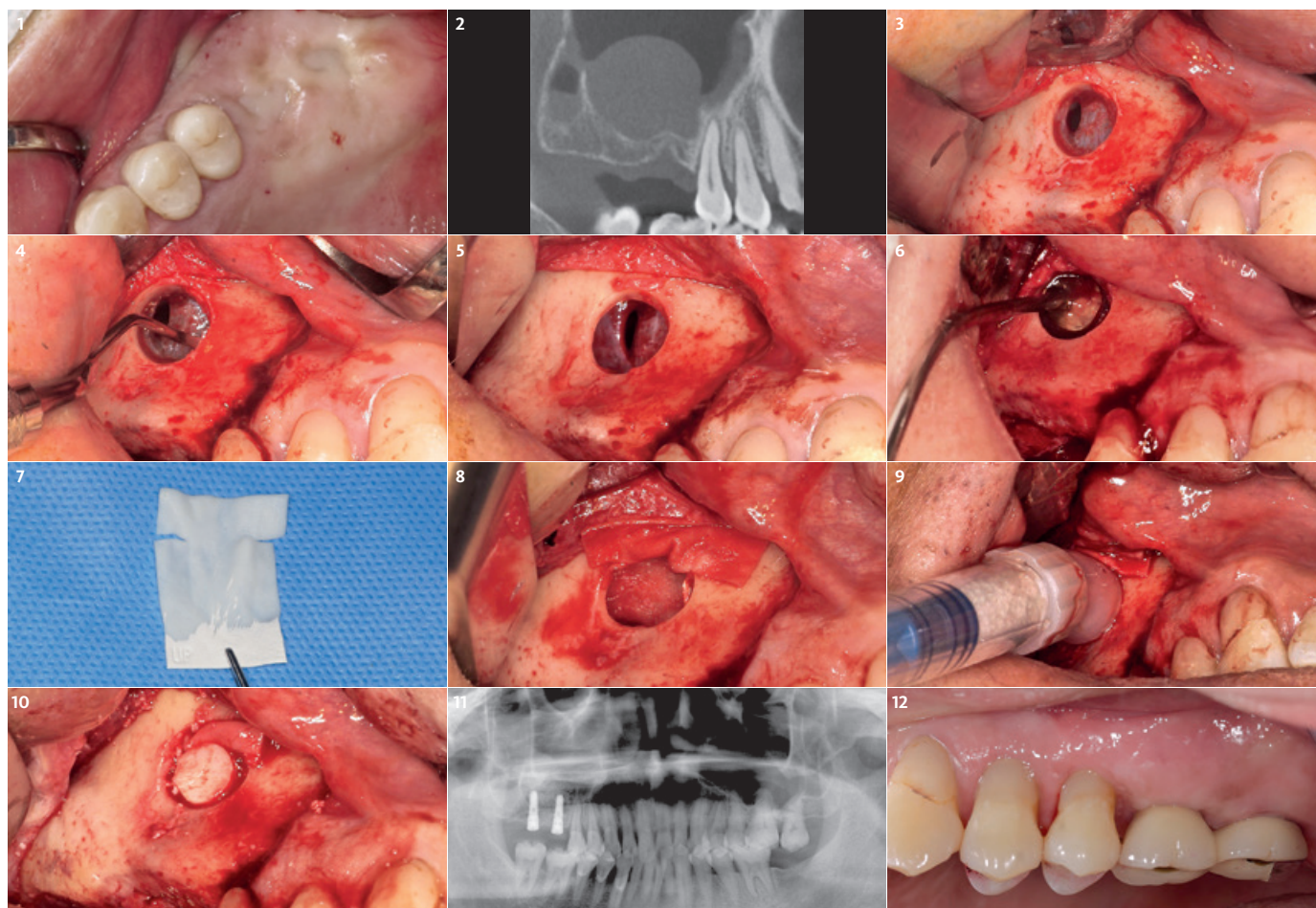
BEFORE



AFTER



APPROACH	TREATMENT	ADDITIONAL MEANS
<input checked="" type="checkbox"/> Lateral	<input checked="" type="checkbox"/> Geistlich Bio-Oss® Pen	<input checked="" type="checkbox"/> One-stage
<input type="checkbox"/> Crestal	<input checked="" type="checkbox"/> Geistlich Bio-Gide®	<input type="checkbox"/> Two-stage
<input type="checkbox"/> Bone Regeneration		



1 Preoperative intraoral view showing the clinical situation.

2 In the preoperative CBCT scan, an antral pseudocyst was observed.

3 After lateral window preparation, a perforated Schneiderian Membrane was visible.

4 Careful membrane elevation was performed from the opposite side of the perforation.

5 The elevation around the perforation was performed without propagation of the perforation.

6 The antral pseudocyst was aspirated with a needle through the perforated membrane.

7 Geistlich Bio-Gide® was trimmed to repair the perforation. Two horizontal cuts were made at the upper ¼ of the part. This ¼ upper part was placed outside the sinus cavity on the lateral wall.

8 The trimmed Geistlich Bio-Gide® was placed to cover the perforated Schneiderian membrane. The upper ¼ of Geistlich Bio-Gide® was outside of the cavity and the lower ¾ part was inserted inside.

9 Easy and fast application of Geistlich Bio-Oss Pen® into the cavity. Please note the upper ¼ part of Geistlich Bio-Gide® was kept in place by the tip of the Geistlich Bio-Oss Pen®.

10 The bony window was relocated to its original position for covering the lateral window.

11 Postoperative panoramic radiographic image. Site with augmented sinus floor and 2 dental implants placed simultaneously are visible.

12 Clinical picture at the 1-year follow-up time after the final restoration. (mirror image).

Lateral sinus floor elevation with large sinus membrane perforation



Assoc. Prof. Prisana Pripatnanont, DDS | Hatyai, Thailand

CLINICAL CHALLENGE

In this case a long term follow-up of a sinus floor augmentation was carried out. A large Schneiderian membrane perforation was repaired using Geistlich Bio-Gide® and platelet-rich fibrin (PRF), and a sinus floor grafting was performed with Geistlich Bio-Oss® particles. A 61-year old woman came to the dental office and asked for an implant-supported prosthesis in the area of the left 2nd premolar and 1st molar. The edentulous area had a bone height of 4–5 mm. A sinus floor elevation was planned followed after 7 months by implant placement. During the opening of the lateral window to the sinus floor, a Schneiderian membrane perforation occurred caused by the rotary bur due to a very thin Schneiderian membrane. In order to repair the complete perforation site

Geistlich Bio-Gide® and PRF were used to cover the perforation. Afterwards the sinus floor was elevated with 1 g of Geistlich Bio-Oss® particles. The implant had been placed 7 months after augmentation with a good primary stability. Prosthesis construction was done 4 months after implant placement. After a 2-year follow-up period, the implant showed no marginal bone resorption, the bone grafting area showed minimal volume change and good support to the implants.

AIM/APPROACH

To demonstrate the efficiency of Geistlich Bio-Gide® for repairing a large Schneiderian membrane perforation and good long term stability of Geistlich Bio-Oss® granules in sinus graft procedures showed minimal volume change.

CONCLUSION

Geistlich Bio-Gide® is effectively used for repairing major sinus membrane perforation and sinus augmentation with Geistlich Bio-Oss® granules is effective in bone support and stable volume.

Clinical outcome at a glance

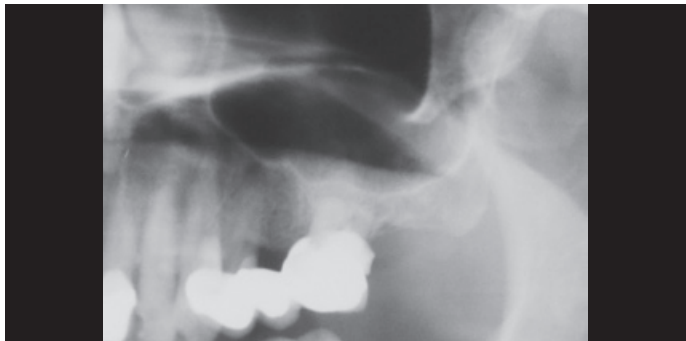OBJECTIVES

- > Sinus floor elevation using Geistlich Bio-Oss® and Geistlich Bio-Gide®.
- > Repairing a large Schneiderian membrane perforation with Geistlich Bio-Gide®.

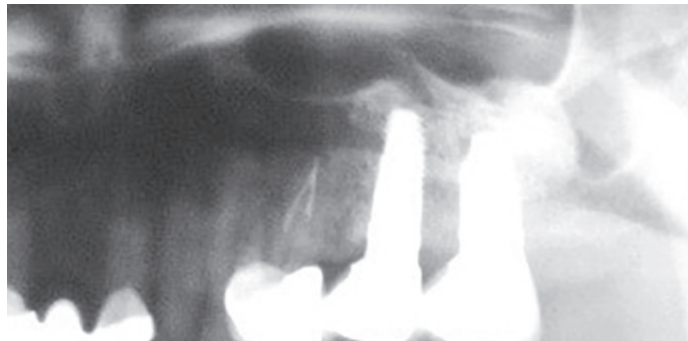
CONCLUSIONS

- > Two-stage sinus floor elevation treatment.
- > Effective bone support and stable bone volume by using Geistlich Bio-Oss®.
- > Effective application of a Geistlich Bio-Gide® in a large Schneiderian membrane perforation.

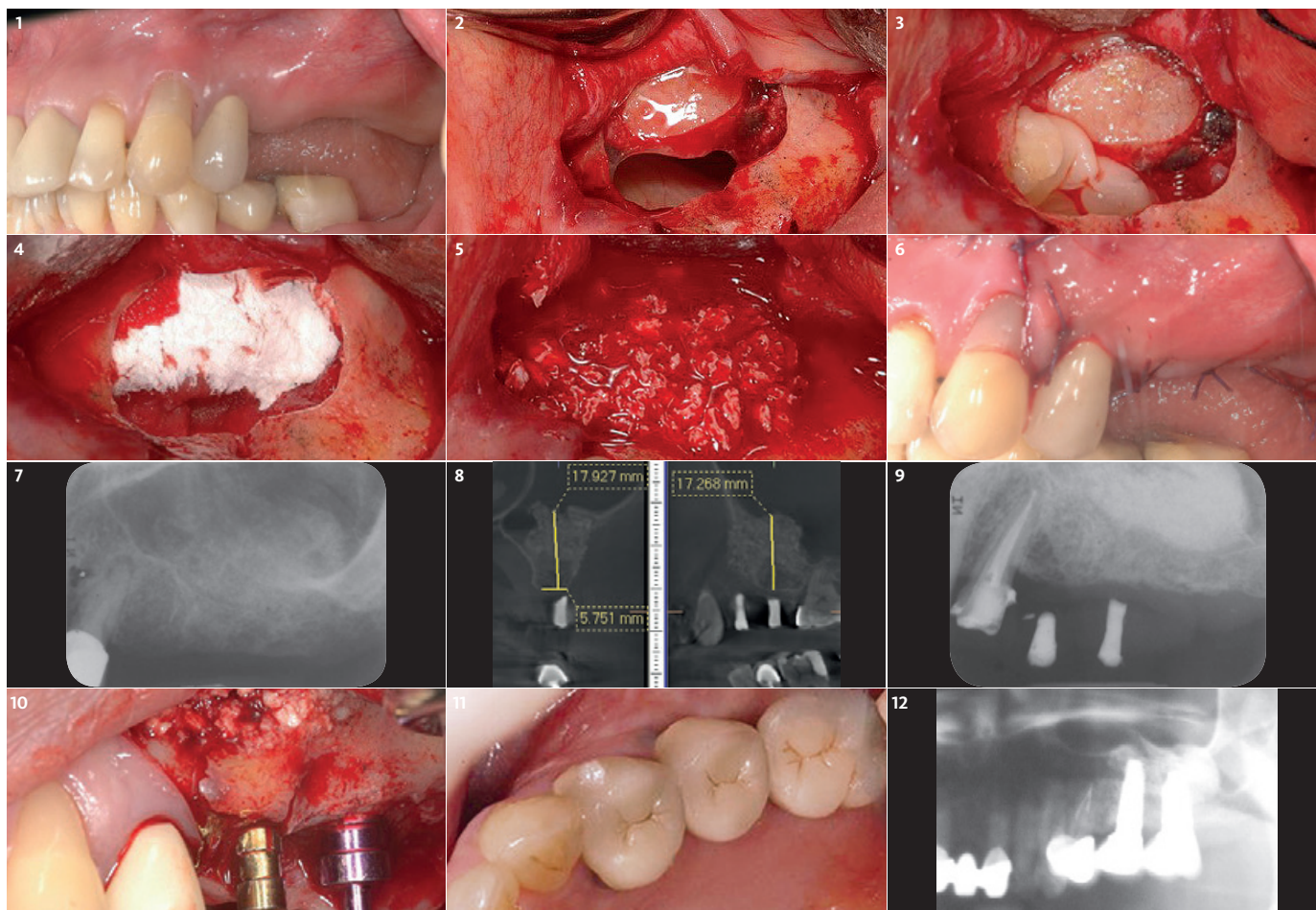
BEFORE



AFTER



APPROACH	TREATMENT	ADDITIONAL MEANS
<input checked="" type="checkbox"/> Lateral	<input checked="" type="checkbox"/> Geistlich Bio-Oss®	<input type="checkbox"/> One-stage
<input type="checkbox"/> Crestal	<input checked="" type="checkbox"/> Geistlich Bio-Gide®	<input checked="" type="checkbox"/> Two-stage
<input type="checkbox"/> Bone Regeneration		



1 Areas 25, 26 planned for sinus augmentation via lateral approach and later implant placement.

2 Intraoperative picture shows sinus window and large perforation of sinus membrane size 5x10 mm at the lower border of the window.

3 Intraoperative picture after membrane lifting and covering sinus membrane perforation with platelet-rich fibrin (PRF).

4 Geistlich Bio-Gide® covers the PRF before filling the grafting material.

5 Geistlich Bio-Oss® was used as a grafting material which was mixed with serum from platelet-rich fibrin and filled in the sinus lifted space.

6 Intra-oral view shows immediate post-operative wound.

7 Periapical film immediately post-operative shows Geistlich Bio-Oss® grafting material distributed in the augmented area.

8 Cone beam CT at seven months post-operatively shows better density of augmented area and Geistlich Bio-Oss® granules were aggregated together and confined to the repair zone.

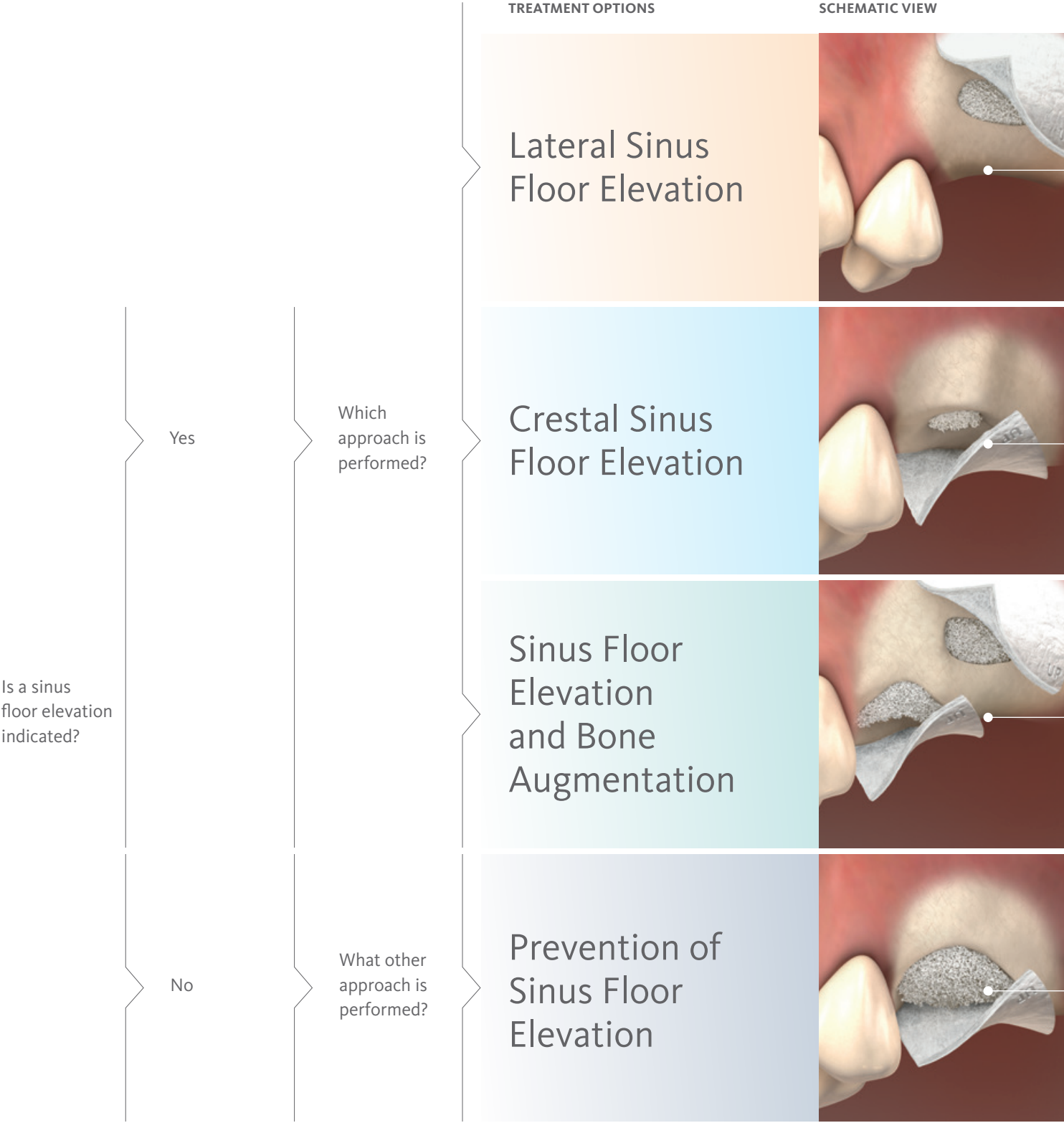
9 7 months after sinus augmentation the implant placement was planned. The augmented area shows Geistlich Bio-Oss® granules at a higher density compared to the immediate post-op situation.

10 7 months after sinus augmentation, two implants with primary stability were placed. The augmented area shows well integrated Geistlich Bio-Oss® granules surrounded with newly formed bone.

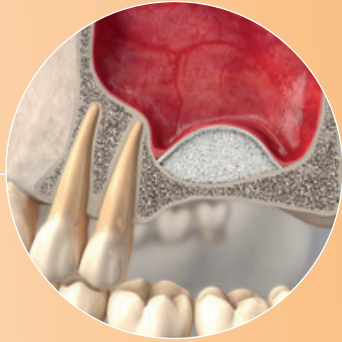
11 One year after sinus augmentation a complete crown restoration had been achieved.

12 Two years and 3 months after sinus augmentation shows the sinus graft to be in a stable condition with minimal volume change.

Treatment Options Maxillary Sinus Area



RECOMMENDED MATERIAL

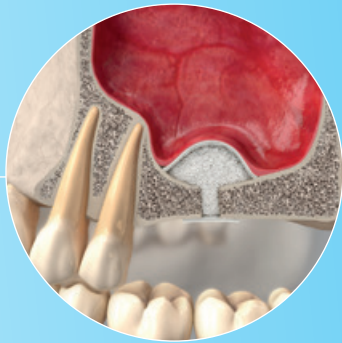


See all clinical cases "lateral sinus floor elevation" online here



Geistlich Bio-Oss® or
Geistlich Bio-Oss Pen®

Geistlich Bio-Gide® or
Geistlich Bio-Gide® Compressed

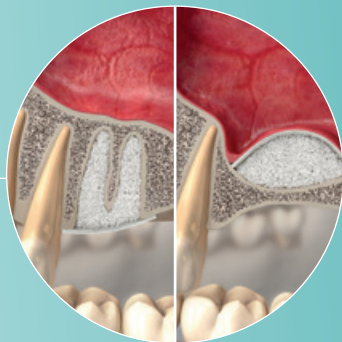


See all clinical cases "crestal sinus floor elevation" online here



Geistlich Bio-Oss® or
Geistlich Bio-Oss® Collagen

Geistlich Bio-Gide® or
Geistlich Bio-Gide® Compressed

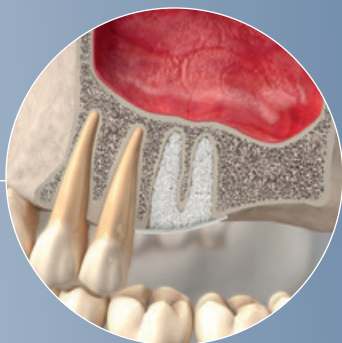


See all clinical cases "Sinus Floor Elevation and Bone Augmentation" online here



Geistlich Bio-Oss®,
Geistlich Bio-Oss® Collagen or
Geistlich Bio-Oss Pen®

Geistlich Bio-Gide® or
Geistlich Bio-Gide® Compressed




See all clinical cases "Prevention of Sinus Floor Elevation" online here



Geistlich Bio-Oss®,
Geistlich Bio-Oss® Collagen or
Geistlich Bio-Oss Pen®

Geistlich Bio-Gide® or
Geistlich Bio-Gide® Compressed



Double crestal sinus floor elevation



Dr. Feng Bo | Hunan, China

CLINICAL CHALLENGE

Alveolar bone resorption in posterior maxilla and maxillary sinus pneumatization always challenges the implant placement. Maxillary sinus floor elevation and onlay bone grafting are the regular methods for solving these problems. Two main approaches for the maxillary sinus floor elevation procedure are now widely used in dental clinics. Lateral antrostomy is mostly used in severe alveolar bone resorption but one of the drawbacks of the lateral antrostomy is that it requires the raising of a large flap for surgical access. The crestal approach is considered to be a more conservative method. This case report demonstrates a minimally invasive technique for the management of vertical ridge defects (less than 1 mm) in the posterior maxilla. The double-crestal-approach provides clinicians a

simple, convenient and minimally invasive approach compared to the regular lateral antrostomy.

AIM/APPROACH

Treatment was carried out under local anaesthesia with local buccal and palatal infiltrations. The proposed implant site was marked with a trephine drill. The depth was controlled within the alveolar bone to protect the sinus membrane from perforation. Then the round bone block was gently tapped and pushed into the maxillary sinus using the sinus lift osteotome. By using the trephine drill, the cut bone block can be used. While the bone block was gently pushed into sinus, the sinus membrane was elevated at the same time. The bone block provides the osteoblast while the connected sinus membrane provides the blood supply. The osteoblast and blood supply are the key factors for

bone ossification. The Schneiderian membrane near to the bone block was slightly dissected using an antral curette. Then the bone block was elevated again for about 4 mm. A space is created by the intruded bone block. This space is then grafted with Geistlich Bio-Oss®. Geistlich Bio-Gide® was adapted to overlay the osteotomy site. The second sinus floor elevation was performed six months later with the same procedure.

CONCLUSION

The dual-crestal approach combined with the placement of a short implant is an efficient method for overcoming the severe posterior maxilla bone resorption. Elevating the sinus floor by a crestal approach twice reduces the use of bone grafting material, saves surgical time and cost, and leads to fewer postoperative complications.

Clinical outcome at a glance

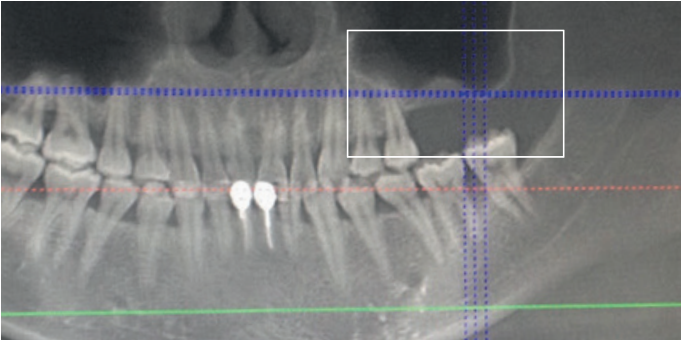
OBJECTIVES

- > Dual sinus floor elevation with dual-crestal approach using Geistlich Bio-Oss® and Geistlich Bio-Gide®.
- > Short implant placement due to severe bone resorption.

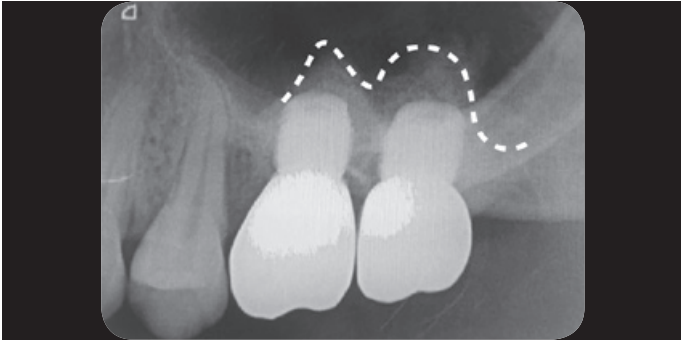
CONCLUSIONS

- > Dual-crestal sinus floor elevation using Geistlich Bio-Oss® and Geistlich Bio-Gide® in combination with short implant placement overcome severe bone resorption.
- > Fewer postoperative complications using Geistlich Biomaterials in combination with dual-crestal sinus floor elevation.

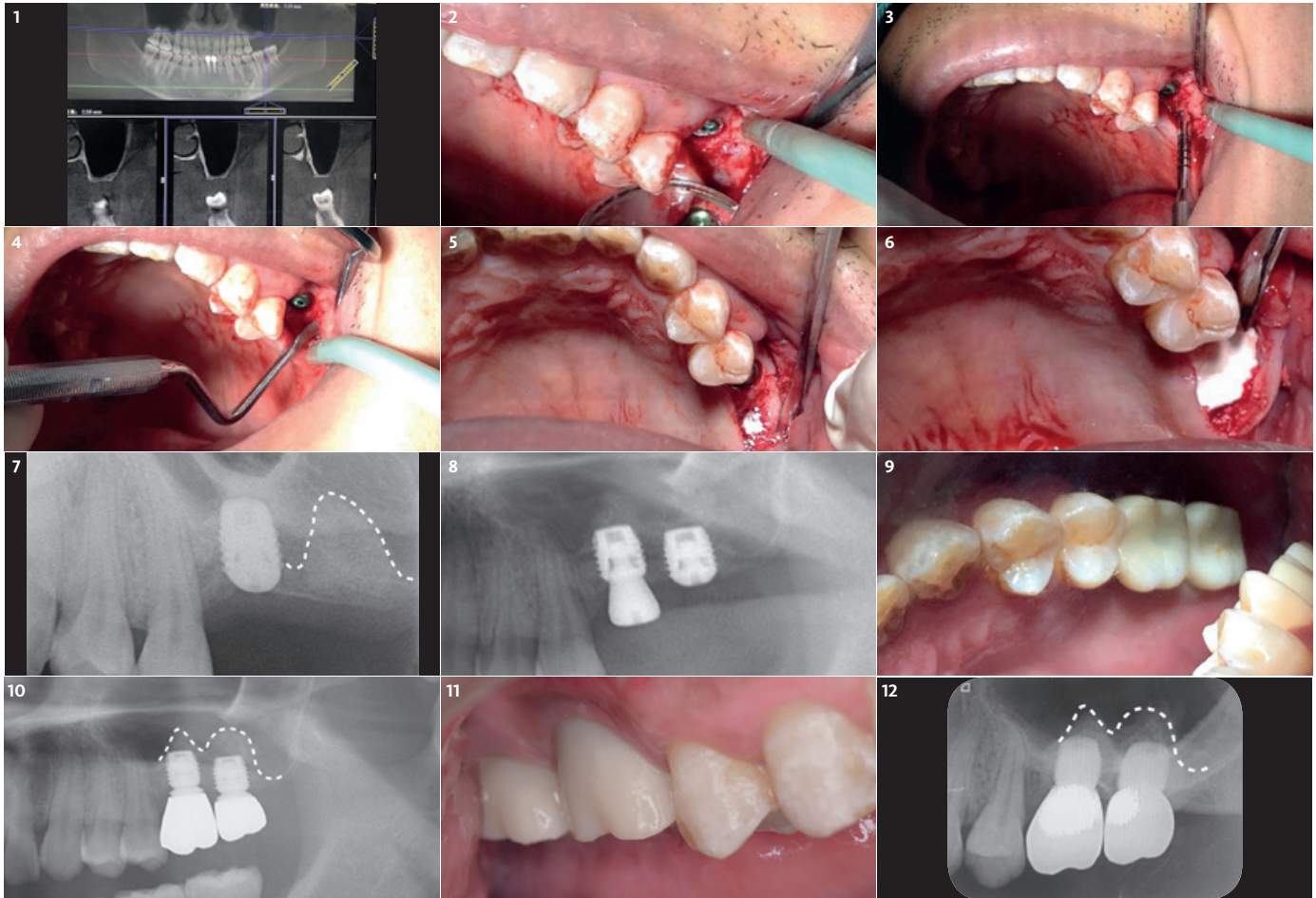
BEFORE



AFTER



APPROACH	TREATMENT	ADDITIONAL MEANS
<input type="checkbox"/> Lateral	<input checked="" type="checkbox"/> Geistlich Bio-Oss®	<input type="checkbox"/> One-stage
<input checked="" type="checkbox"/> Crestal	<input checked="" type="checkbox"/> Geistlich Bio-Gide®	<input checked="" type="checkbox"/> Two-stage
<input type="checkbox"/> Bone Regeneration		



1 Preoperative CBCT of posterior maxillary area shows the alveolar bone's height in region 27 is about 1mm.

2 Intraoperative picture showing the thin alveolar bone after full-thickness flap elevation.

3 First crestal sinus floor elevation in region 27 using the sinus lift osteotome to gently elevate the sinus floor for about 4mm.

4 Elevation of the Schneiderian Membrane from the sinus floor using an antral curette.

5 Augmentation of the elevated sinus floor with Geistlich Bio-Oss®.

6 Covering the regions 26 and 27 with Geistlich Bio-Gide® to protect the augmentation site and prevent soft tissue ingrowth.

7 Radiological picture showing the augmented site in the maxillary cavity after the first crestal sinus floor elevation.

8 6 months postoperative radiological picture showing the second crestal sinus floor elevation using Geistlich Bio-Oss® and Geistlich Bio-Gide® and implant placement.

9 Postoperative clinical situation of the final restoration after 18 months.

10 Postoperative radiological picture of the final restoration 18 months.

11 Clinical picture at recall 2 years after the final restoration showing a stable periodontal situation.

12 Postoperative radiological picture after 2 years with stable bone augmentation.

Lateral sinus floor elevation with 20-year follow-up



Dr. Devorah Schwartz-Arad, DMD, PhD | Tel-Aviv, Israel

CLINICAL CHALLENGE

A 62-old female healthy patient was referred to the Schwartz-Arad surgical center for an extraction of the first right maxillary molar. This clinical case was performed in 1997 with a 20-year follow-up period. The region of interest is the right maxillary molar. In this region the 1st right maxillary molar was untreatable due to a perio-endo defect. The first and second right maxillary premolars were missing as well. The existing bridge included the right maxillary canine and the first molar. The available alveolar ridge was not sufficient for implant placement due to the pneumatization of the right maxillary sinus and the endo-perio-lesion of the tooth. The patient came for a treatment to obtain a fixed prosthetic restoration. The clinical challenge was to simultaneously reconstruct the ridge volume in the vertical dimension via a sinus augmentation

procedure, and ridge preservation at the time of tooth extraction, for second stage implants placement.

AIM/APPROACH

Sinus augmentation procedure via lateral window approach²⁴

Prophylactic oral pre-medication of amoxicillin (1 g) and dexamethasone (8 mg) an hour before the procedure and a local application of 0.5% chlorhexidine for 2 min. An incision was made on the alveolar crest and a vertical incision distal to the tuberosity was made to allow bone harvesting from this area to be mixed with the Geistlich Bio-Oss®. A window was cut through the lateral sinus wall cortex using a slow-speed round bone bur. At this point, the sinus membrane was carefully elevated from the sinus floor and medial sinus wall. Geistlich Bio-Gide® was used to repair the perforation. Since primary implant

stability could not be attained, a delayed 2-stage implant placement was performed 5 months later. The maxillary sinus compartment was augmented with Geistlich Bio-Oss®. The fenestrated lateral wall of the maxillary sinus was covered with a Geistlich Bio-Gide® and the mucoperiosteal flap repositioned and sutured with a 3/0 Vicryl.

CONCLUSION

This case, with 20 year follow-up, is only one example of many patients with insufficient alveolar ridges, treated in the Schwartz-Arad surgical center with Geistlich Bio-Oss®. Bone augmentation using Geistlich Bio-Oss® and Geistlich Bio-Gide® for the sinus augmentation procedure is a predictable treatment approach for the long run. Furthermore, sinus membrane perforation did not influence implant success negatively when corrected with Geistlich Bio-Gide®.

Clinical outcome at a glance

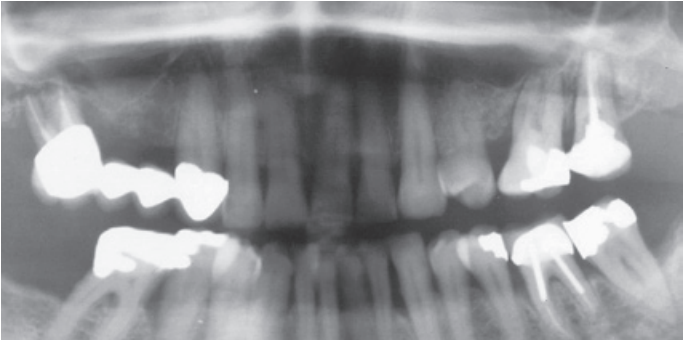
OBJECTIVES

- > Sinus floor elevation through a lateral window.
- > Bone augmentation of the maxillary sinus cavity prior to implant placement after 5 months.

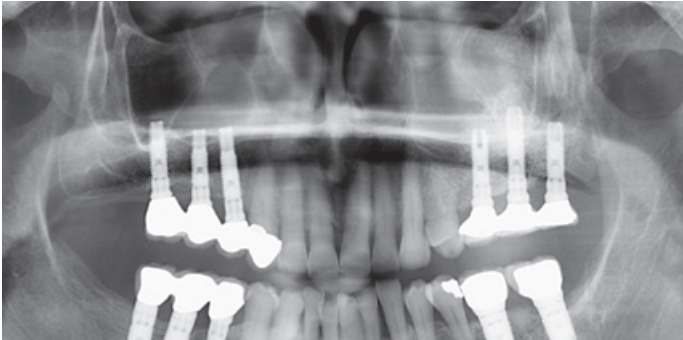
CONCLUSIONS

- > Two-stage sinus floor elevation treatment.
- > Sinus floor elevation using Geistlich Bio-Oss® and Geistlich Bio-Gide® leads to long-term clinical success.
- > Perfect prosthetic situation after 20-year follow-up.

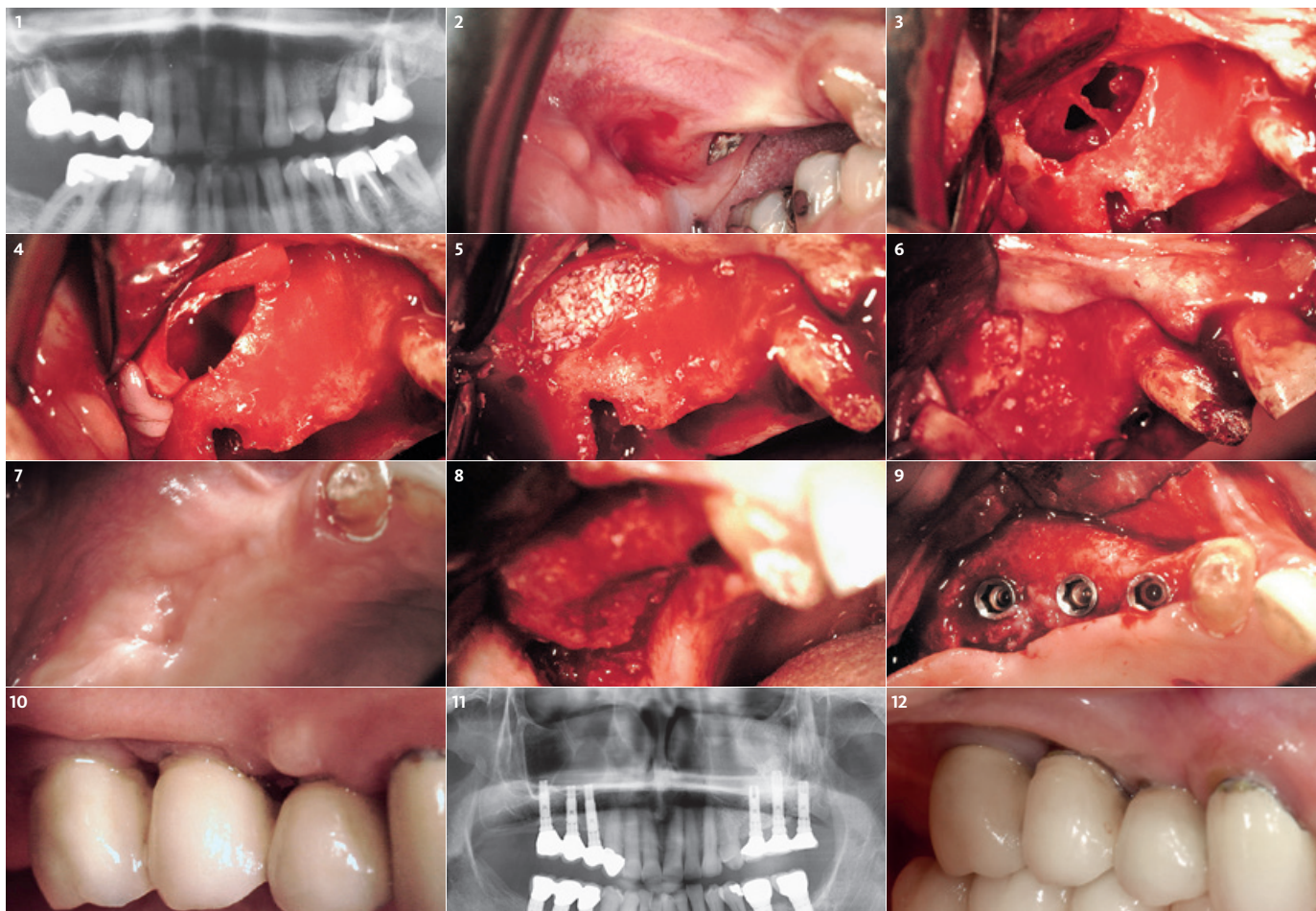
BEFORE



AFTER



APPROACH	TREATMENT	ADDITIONAL MEANS
<input checked="" type="checkbox"/> Lateral	<input checked="" type="checkbox"/> Geistlich Bio-Oss®	<input type="checkbox"/> One-stage
<input type="checkbox"/> Crestal	<input checked="" type="checkbox"/> Geistlich Bio-Gide®	<input checked="" type="checkbox"/> Two-stage
<input checked="" type="checkbox"/> Bone Regeneration		



1 Radiological preoperative panoramic view in 1997. Region of interest is on the right side.

2 Clinical preoperative view of the right side in 1997.

3 Right maxillary sinus augmentation, with severe Schneiderian membrane perforation, before using Geistlich Bio-Oss® and Geistlich Bio-Gide®.

4 Intraoperative view after placing Geistlich Bio-Gide® in the maxillary sinus cavity to repair the Schneiderian membrane perforation.

5 Intraoperative view after placing Geistlich Bio-Oss® in the sinus floor cavity.

6 Repositioning of the lateral window, covering the lateral window with a Geistlich Bio-Gide®, implant placement in region 14 and ridge preservation in region 15, 16.

7 Occlusal view 5 months after sinus floor augmentation with Geistlich Bio-Oss® and Geistlich Bio-Gide®.

8 5 months after sinus floor augmentation clinical situation at the time the implants were placed.

9 Clinical situation 5 months after sinus augmentation and after implant placement.

10 After permanent restoration 2.5-year follow-up view of the clinical situation.

11 Radiological picture after 20-year follow-up with stable bone volume on the right side.

12 Buccal clinical view after 20-year follow-up.

Lateral sinus floor elevation in combination with 3D via F. Khoury’s technique



Dr. Mehdi Merabet | Marseille, France

CLINICAL CHALLENGE

- › A pneumatized sinus cavity was localized in the area of the anterior maxilla.
- › Due to the atrophic alveolar crest it was impossible to place the implant in a correct position to achieve an appropriate esthetic rehabilitation.

AIM/APPROACH

- › Lateral sinus floor elevation with Geistlich Bio-Oss® was performed in the area of the right canine/premolar. In this case the minimal invasive lateral window approach allows a better blood supply in the reconstructed region.
- › Following the sinus floor elevation a bone reconstruction of the alveolar crest was performed with 3D using F. Khoury’s technique. The bone block was harvested from the ramus. After preparation of the two blocks each were fixed with a screw in the upper frontal area. The residual spaces between and around the blocks were filled with a mix of Geistlich Bio-Oss® particles and autogenous bone chips.

CONCLUSION

- › Grafting with Geistlich Bio-Oss® particles in the sinus cavity maintains the long term stability of the regenerated bone volume. It provides the patient a comfortable and predictable solution.
- › Reconstructing the alveolar crest with 3D via F. Khoury’s technique in combination with the use of Geistlich Bio-Oss® minimizes the volume/size of the harvested bone block. Due to the slow resorption rate of Geistlich Bio-Oss® particles the bone volume is maintained and therefore the aesthetic result.

Clinical outcome at a glance

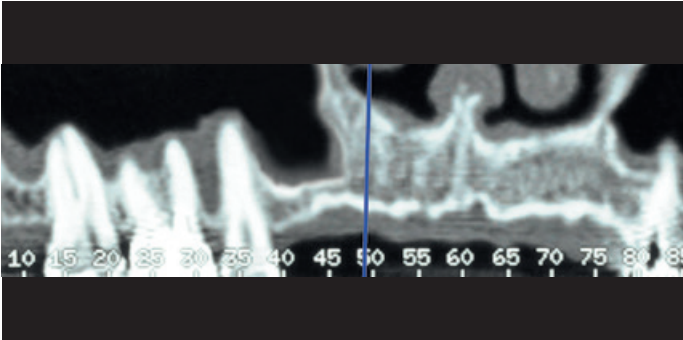
OBJECTIVES

- › Later sinus floor elevation in combination with bone regeneration with 3D using F. Khoury’s technique.
- › Fixed prosthetic restoration in the upper and anterior area.

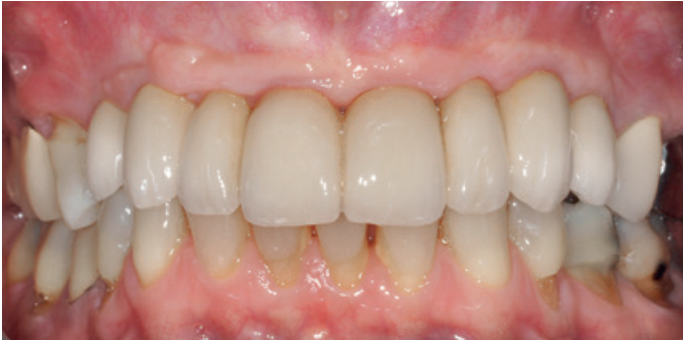CONCLUSIONS

- › Two-stage sinus floor elevation treatment.
- › Sinus floor elevation using Geistlich Bio-Oss® maintains long term stability of the augmented bone volume.
- › Using Geistlich Bio-Oss® particles in combination with autologous bone chips limits the resorption rate of the augmented site.

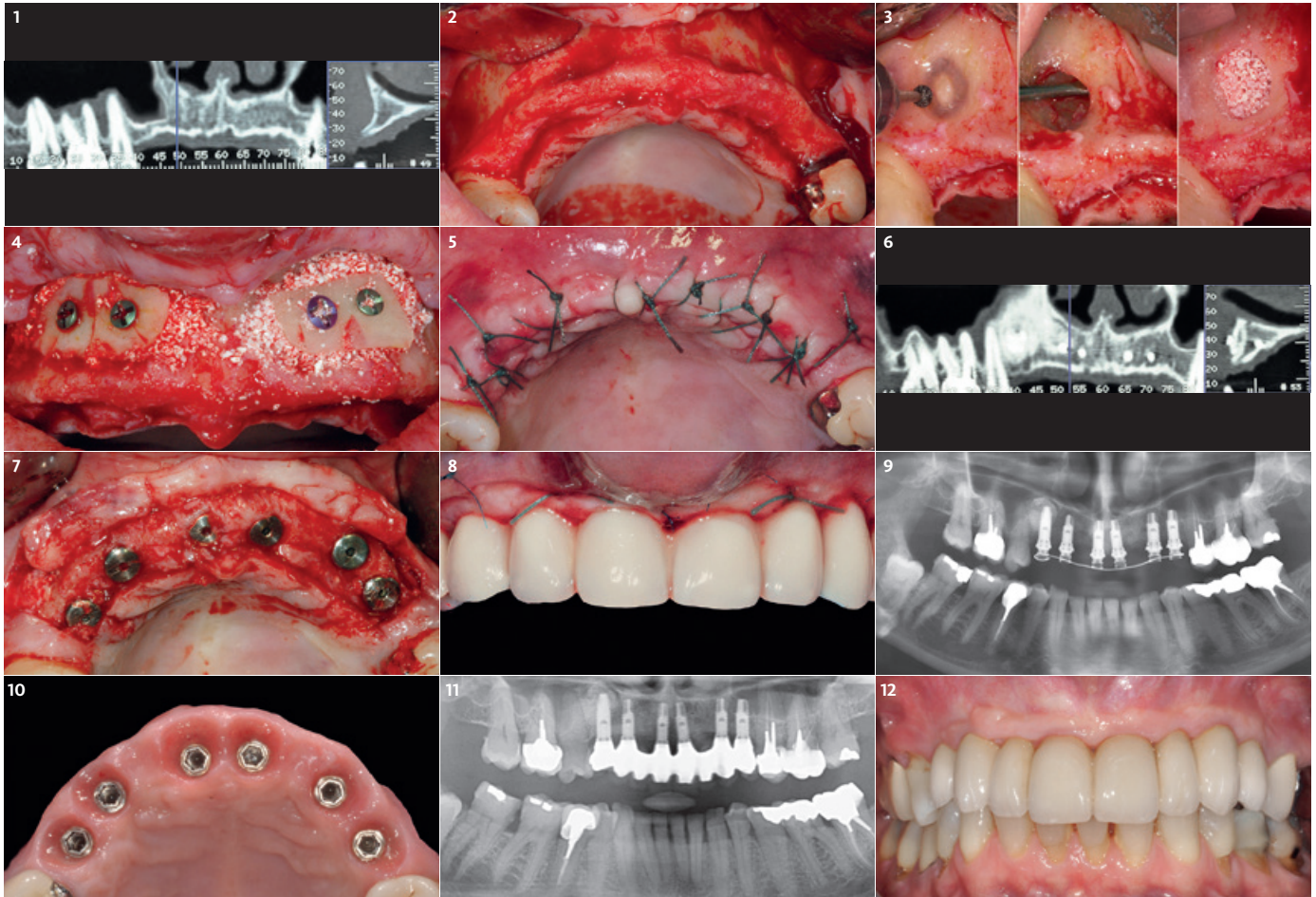
BEFORE



AFTER



APPROACH	TREATMENT	ADDITIONAL MEANS
<input checked="" type="checkbox"/> Lateral	<input checked="" type="checkbox"/> Geistlich Bio-Oss®	<input type="checkbox"/> One-stage
<input type="checkbox"/> Crestal	<input type="checkbox"/> Geistlich Bio-Gide®	<input checked="" type="checkbox"/> Two-stage
<input checked="" type="checkbox"/> Bone Regeneration	<input checked="" type="checkbox"/> autologous bone	



1 Preoperative radiography: panoramic slice of CT scan showing pneumatized sinus in canine area, combined with a coronal slice (n° 49) highlighting an atrophic alveolar crest.

2 Intraoral buccal view showing an atrophic alveolar crest.

3 Sinus floor elevation with a minimal invasive lateral approach filled with Geistlich Bio-Oss® particles.

4 Alveolar crest reconstruction with a bone block (F. Khoury's technique). After fixation of the bone block the residual space was filled with a mix of 50% of autogenous bone and 50% Geistlich Bio-Oss®.

5 Modified cross and U sutures in order to maintain the flap airtight.

6 6-month postoperative radiography: panoramic slice of CT scan showing sinus graft result combined with a coronal slice (n° 53) highlighting a horizontal bone reconstruction.

7 Second surgery at 6-months postoperative: osteosynthesis screw is removed and dental implants are placed in the right 3D position according to the aesthetic project.

8 Intraoral view 12 months postoperative showing the 3rd surgery: temporary prosthesis restoration combined with a bilateral connective tissue graft from the palate.²⁵


9 15-month postoperative radiography showing the temporary prosthesis in function.

10 Occlusal intraoral view 15-months postoperative showing the tissue volume reconstructed and implant placement.

11 6-year postoperative radiography showing a stable bone volume.

12 Intraoral clinical view after 6-years postoperative showing a stable tissue volume.

Lateral sinus floor elevation in combination with guided bone regeneration



Dr. Joao Batista César Neto, Dr. Luiz Antonio Ruy | Sorocaba, Brazil

CLINICAL CHALLENGE

A difficult case of oral rehabilitation with a particular challenge at regions 15 and 16. The patient had a car accident some years before and was hit in this area. It resulted in an anatomical change to the sinus with partial loss of buccal sinus wall and scar tissue inside part of the sinus.

AIM/APPROACH

During flap reflection, the scar tissue was dissected and part of it removed. After this step, a Geistlich Bio-Gide® membrane was placed to isolate the fibrotic tissue present in the superior part of the sinus. Then the sinus membrane was elevated in the medial region of the sinus. The sinus cavity was filled with Geistlich Bio-Oss® which was also used to regenerate the ridge deficiency. Geistlich Bio-Gide® was stabilized buccally with bone tacks and packed in the palate.

CONCLUSION

This approach was able to regenerate both the sinus and ridge bone deficiency in one surgery.

Clinical outcome at a glance

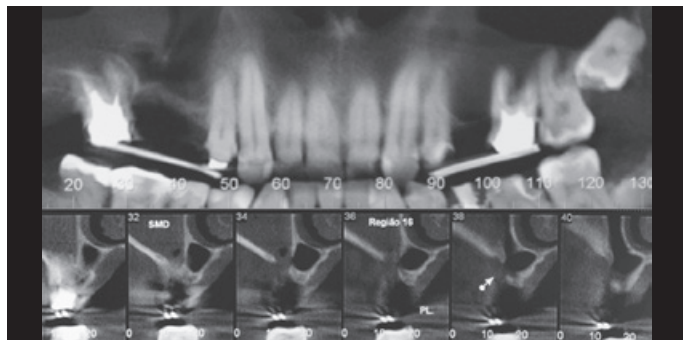
OBJECTIVES

- > Challenging due to anatomic variations caused by previous car accident.
- > Sinus floor elevation with lateral window approach in combination with a guided bone regeneration.
- > Implant placement at 10 months after bone augmentation.

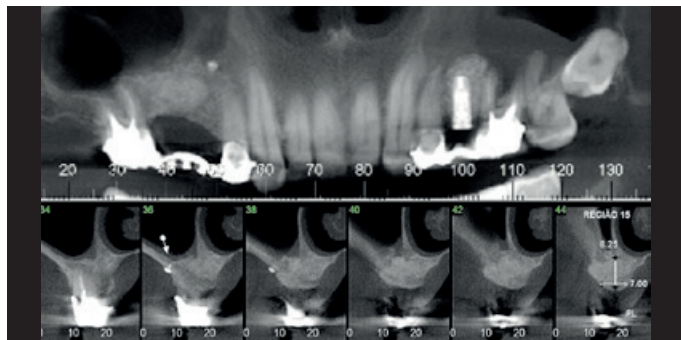
CONCLUSIONS

- > Two-stage sinus floor elevation treatment.
- > A sinus floor elevation in combination with a guided bone regeneration using Geistlich Bio-Oss® and Geistlich Bio-Gide® leads to stable bone volume for implant placement.

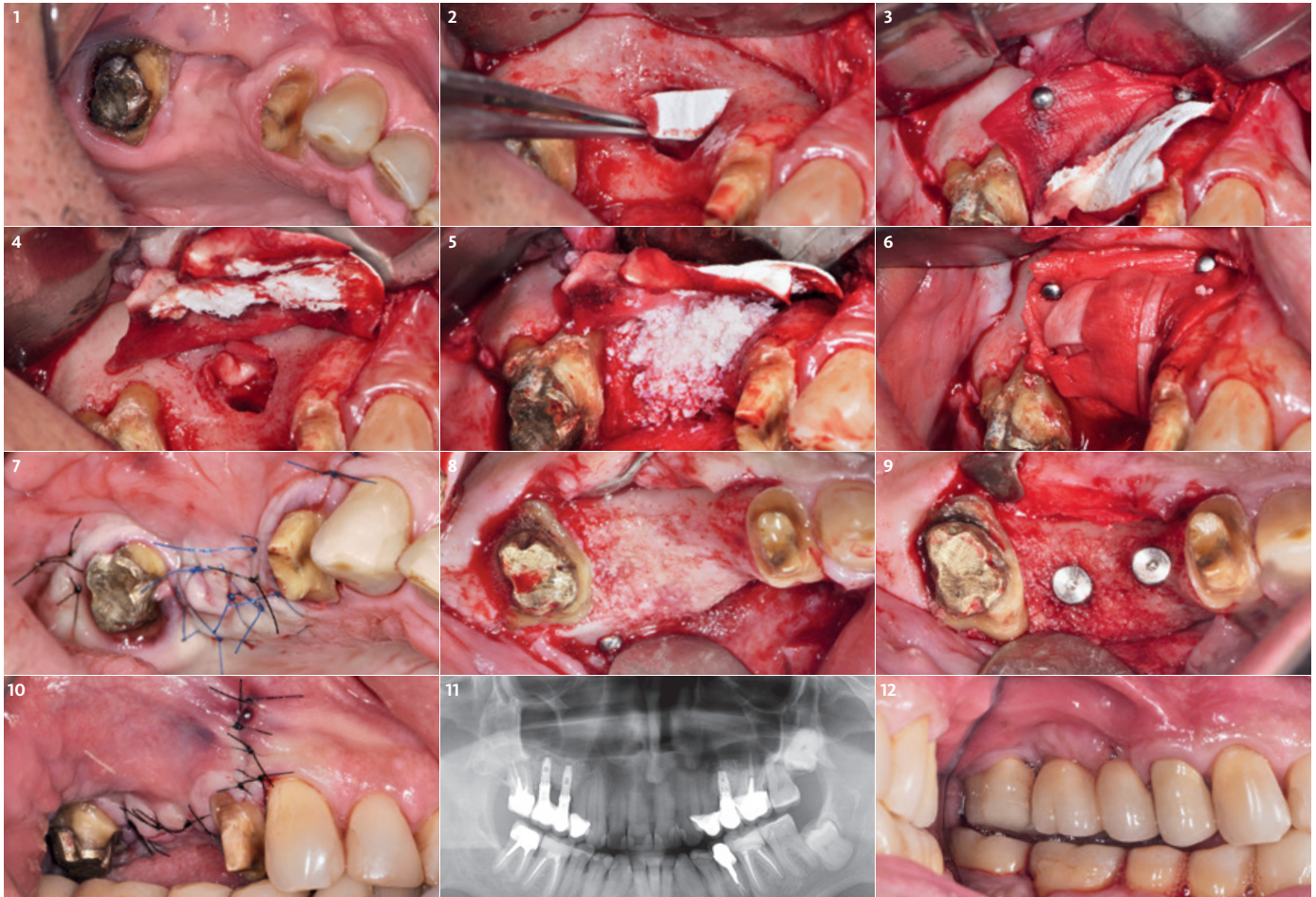
BEFORE



AFTER



APPROACH	TREATMENT	ADDITIONAL MEANS
<input checked="" type="checkbox"/> Lateral	<input checked="" type="checkbox"/> Geistlich Bio-Oss®	<input type="checkbox"/> One-stage
<input type="checkbox"/> Crestal	<input checked="" type="checkbox"/> Geistlich Bio-Gide®	<input checked="" type="checkbox"/> Two-stage
<input checked="" type="checkbox"/> Bone Regeneration		



1 Pre-operative occlusal view.

2 Cut to size Geistlich Bio-Gide® covers fibrotic tissue present in the superior part of the sinus.

3 Geistlich Bio-Gide® trimmed for ridge reconstruction and stabilized with bone tacks placed apically to the sinus window.

4 Final position of Geistlich Bio-Gide® used to isolate fibrotic tissue caused by previous trauma.

5 Geistlich Bio-Oss® placed inside the sinus and also correcting the bone deficiency in the first third of the ridge.

6 Final position of Geistlich Bio-Gide®. It was positioned buccally with bone tacks and packed under the palatal flap. Note: remaining pieces were used to additionally isolate the buccal area.

7 Immediate postoperative, a combination of horizontal mattresses and single interrupted sutures.

8 Occlusal view of the regenerated tissue at implant surgery, 10 months after the bone grafting.


9 Implant position. Note that narrow implants (3.25 x 10 mm and 3.25 x 8 mm) were used due to the limited space in the edentulous region.

10 Sutures after implant placement.

11 Panoramic radiographic 3 years after the bone grafting. Note the stability of the regenerated tissue and that both sides were restored.

12 Clinical image of the final restoration 3 years after the bone grafting and 2 years and 2 months after implant placement.

Alveolar ridge preservation in posterior maxillary teeth for prevention of sinus floor elevation procedures



Dr. Ryan SB Lee, Dr. Lisetta Lam, Prof. Saso Ivanovski | Brisbane, Australia

CLINICAL CHALLENGE

The combination of alveolar bone resorption and sinus pneumatization following tooth extraction reduces available vertical bone height for future implant placement and increases the need for sinus augmentation. Techniques for sinus augmentation such as transalveolar or lateral window approaches, which despite good predictability, are likely to cause additional patient morbidity, increase the risk of complications (e.g. sinus membrane perforation) and increase treatment costs and time.^{26,27} Another alternative treatment approach may involve the use of short implants (< 6 mm in length) in the posterior maxilla, however there is currently insufficient clinical evidence regarding its long term success.^{28,29}

AIM/APPROACH

Alveolar ridge preservation in the posterior maxilla was performed to reduce the need for sinus augmentation procedures. CT scans were taken prior to extraction to assess the baseline vertical bone height. Following extraction, the socket was thoroughly debrided to remove all inflammatory or infective tissues, then, the integrity of the buccal plate was inspected. Deproteinized bovine bone mineral (Geistlich Bio-Oss®, 0.25–1.0 mm) were incrementally and firmly packed into the socket 0.5mm above the alveolar crest. Porcine collagen membrane (Geistlich Bio-Gide®) was then trimmed and covered the socket to prevent the loss of the grafted particles and provide the wound stability. Furthermore, an internal criss-cross suture³⁰ technique was used to achieve membrane and graft stabilization without primary

closure. Postoperative antibiotics and antiseptic mouth-rinses were prescribed. Sutures were removed after two weeks. After a healing period of 4 months, a clinical review and post-extraction CT scan were performed to assess any changes in vertical ridge height and sinus volume.

CONCLUSION

Alveolar ridge preservation following extraction of maxillary posterior teeth may minimize post-extraction remodelling and sinus pneumatization, thus reducing the need for sinus augmentation procedures prior to implant placement.

Clinical outcome at a glance

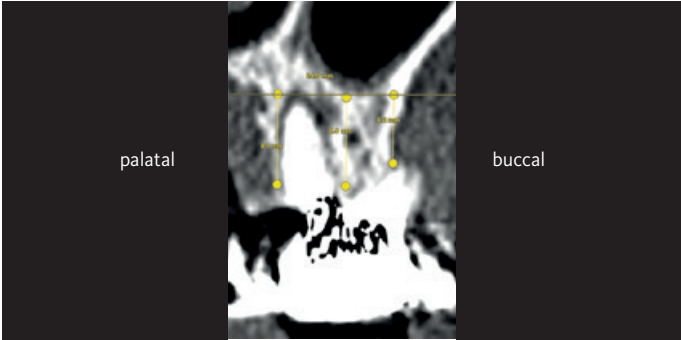
OBJECTIVES

- > Alveolar ridge preservation in the posterior maxillary dentition.
- > Reduction of needs for sinus augmentation procedures.

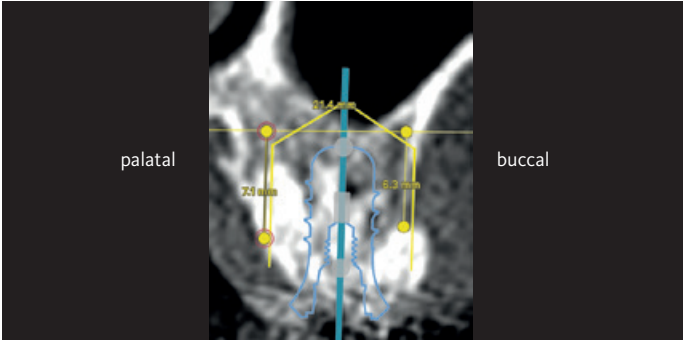
CONCLUSIONS

- > Alveolar ridge preservation with Geistlich Bio-Oss® and Geistlich Bio-Gide® reduces the need for a sinus augmentation procedure prior to implant placement.

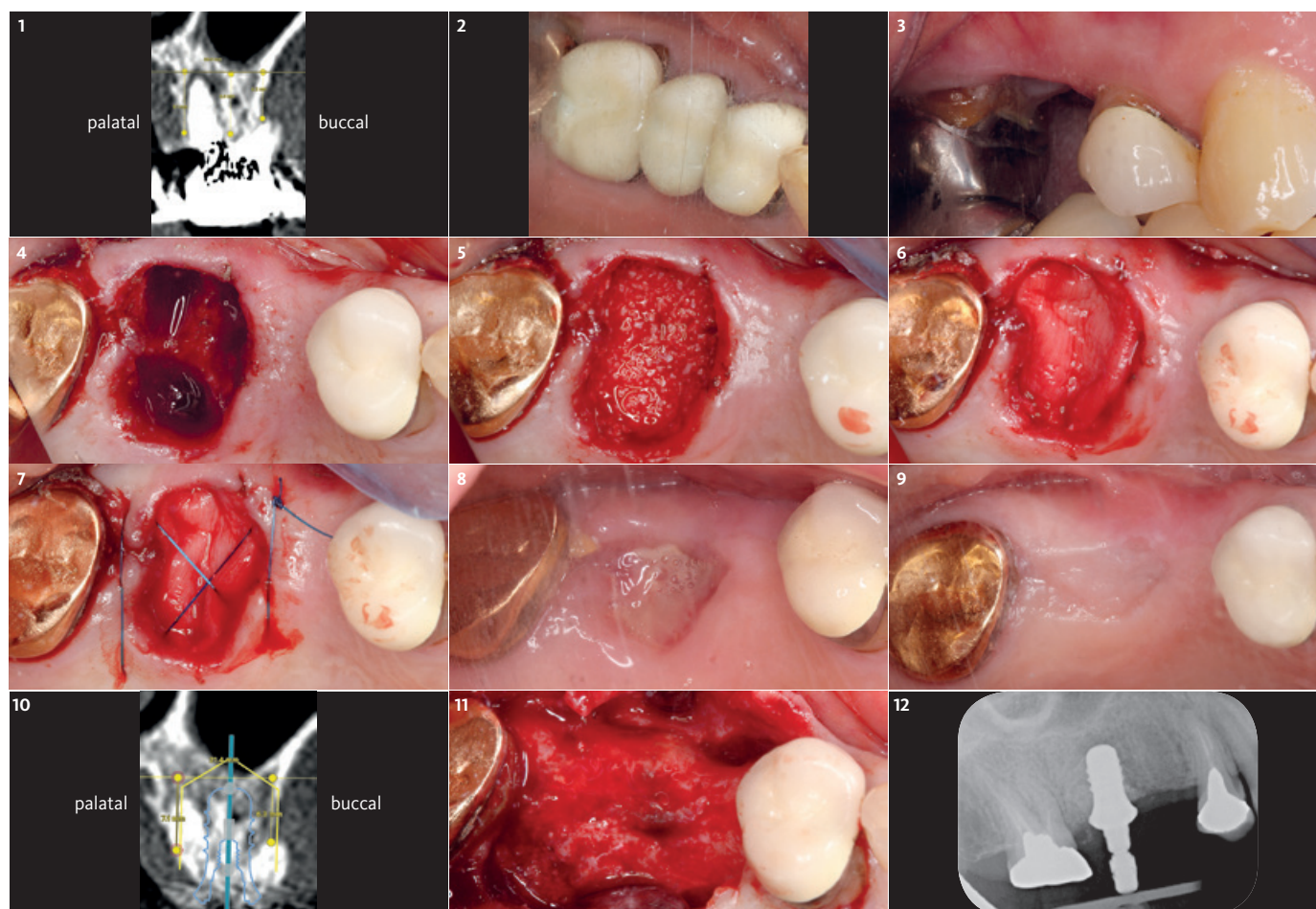
BEFORE



AFTER



APPROACH	TREATMENT	ADDITIONAL MEANS
<input type="checkbox"/> Lateral	<input checked="" type="checkbox"/> Geistlich Bio-Oss®	<input checked="" type="checkbox"/> One-stage
<input type="checkbox"/> Crestal	<input checked="" type="checkbox"/> Geistlich Bio-Gide®	<input type="checkbox"/> Two-stage
<input checked="" type="checkbox"/> Bone Regeneration		



1 16 root fracture, failed root-canal treatment and close proximity to sinus floor. Alveolar bone crest to horizontal line along sinus floor: buccal 6.2 mm, mid-ridge height 8 mm, palatal 8.1 mm.

2 Pre-operative clinical presentation with 3 unit bridge (16–14).

3 The bridge sectioned and the pontic (15) removed, presenting 2–3 mm CAL (clinical attachment level) loss at 16 mesial and 14 distal.

4 Extraction of 16 without raising a full-thickness mucoperiosteal flap; intact buccal socket wall. Socket debridement. Socket dimension: mesial-distal 9.5 mm, buccolingual 10.5 mm.

5 Alveolar ridge preservation using Geistlich Bio-Oss® (0.25–1.0 mm) packed and slightly overfilled the socket above the alveolar crest (0.5 mm).

6 Geistlich Bio-Gide® membrane application to cover the grafting materials.

7 An internal criss-cross suture (Hidden X) technique is used to achieve the membrane and wound stabilization without primary closure.

8 Healing socket at 16 and suture removal. Note the granulation tissue formation on the exposed membrane.




























9 Healing socket at 16 after 4 months showing an uneventful wound closure.

10 CT scan for implant planning with an 8 mm implant. Grafting material visible on CT images. Vertical bone height measurements (buccal cortex height 6.3 mm, palatal cortex height 7.1 mm).

11 Full thickness mucoperiosteal flap raised, Geistlich Bio-Oss® particles have incorporated into the healed alveolar ridge. Minor horizontal and vertical dimensional changes noted.

12 Implant placement at 16 (Tissue level 8 mm long implant). No further grafting required.

Recommended Material Combinations

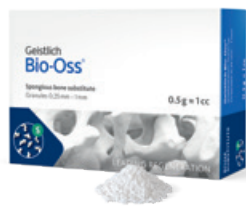	Lateral Sinus Floor Elevation	Crestal Sinus Floor Elevatioin	Sinus Floor Elevation and Bone Augmentation	Prevention of Sinus Floor Elevation
BONE REPLACEMENT MATERIALS				
Geistlich Bio-Oss® Granules 0.25–1 mm 0.25 g ~ 0.5 cm³, 0.5 g ~ 1.0 cm³				
Geistlich Bio-Oss® Granules 0.25–1 mm 1.0 g ~ 2.0 cm³, 2.0 g ~ 4.0 cm³				
Geistlich Bio-Oss® Granules 1–2 mm 0.5 g ~ 1.5 cm³, 1.0 g ~ 3.0 cm³, 2.0 g ~ 6.0 cm³				
Geistlich Bio-Oss Pen® Granules 0.25–1 mm 0.25 g ~ 0.5 cm³				
Geistlich Bio-Oss Pen® Granules 0.25–1 mm 0.5 g ~ 1.0 cm³				
Geistlich Bio-Oss Pen® Granules 1–2 mm 0.5 g ~ 1.5 cm³				
Geistlich Bio-Oss® Collagen 100 mg (5.0 x 5.0 x 7.0 mm), 250 mg (7.0 x 7.0 x 7.0 mm)				
MEMBRANES				
Geistlich Bio-Gide®* 13 x 25 mm				
Geistlich Bio-Gide® 25 x 25 mm				
Geistlich Bio-Gide® 30 x 40 mm				
Geistlich Bio-Gide® Compressed* 13 x 25 mm				
Geistlich Bio-Gide® Compressed* 20 x 30 mm				

* Product availability may vary from country to country

References

- Boyne PJ et al. J Oral Surg. 1980 Aug;38(8):613-6. (clinical study)
- Wheeler SL et al. Int J Oral Maxillofac Implants. 1996 Jan-Feb;11(1):26-34. (clinical study)
- Lee J-E et al. World J Clin Cases. 2014 Nov 16;2(11):683-8. (clinical study)
- Summers RB. Compendium. 1994 Feb;15(2):152, 154-6, 158 passim; quiz 162. (clinical study)
- Tatum H, Jr. 1986. Dental clinics of North America 30(2):207-229. (clinical study)
- Krennmair G et al. Int J Oral Maxillofac Implants. 2007 May-Jun;22(3):351-8. (clinical study)
- Jensen OT et al. Int J Oral Maxillofac Implants. 1998;13 Suppl:11-45. (clinical study)
- Raspirini G et al. Int J Periodontics Restorative Dent. 2010 Jun;30(3):265-73. (clinical study)
- Weng D et al. Eur J Oral Implantol 2011; 4. Supplement: 59–66. (clinical study)
- Chrcanovic BR et al. J Oral Rehabil. 2014 Jun;41(6):443-76. (clinical study)
- Glauser R et al. Clin Implant Dent Relat Res. 2001;3(4):204-13. (clinical study)
- Traini T et al. J Clin Diagn Res. 2016 May;7(5):955-61. (clinical study)
- Palacios JAV et al. 2017. Clin Oral Investig. 2018 Jan;22(1):69-80. (clinical study)
- ITI Treantment Guide Volume 5, Sinus Floor Elevation Procedures. (pre-clinical study)
- US market report suite for dental bone graft substitutes and other biomaterials, iDATA_USD-BGS19_MS, Published in January 2019 by iData Research Inc., 2019. (market research)
- Europe market report suite for dental bone graft substitutes and other biomaterials, iDATA_EUDBGS19_MS, Published in July 2019 by iData Research Inc., 2019. (market research)
- Aghaloo TL et al. Int J Oral Maxillofac Implants. 2007;22 Suppl:49-70. (clinical study)
- Traini T et al. J Periodontol. 2007 May;78(5):955-61. (clinical study)
- Sartori S et al. Clin Oral Implants Res. 2003 Jun;14(3):369-72. (clinical study)
- Erdem NF et al. Implant Dent. 2016 Apr;25(2):214-21. (clinical study)
- Chackartchi T et al. Clin Oral Implants Res. 2011 May;22(5):473-80. (clinical study)
- Wallace SS et al. Ann Periodontol. 2003 Dec;8(1):328-43. (clinical study)
- Wallace SS et al. Int J Periodontics Restorative Dent. 2005 Dec;25(6):551-9. (clinical study)
- Schwartz-Arad D et al. J Periodontol. 2004 Apr;75(4):511-6. (clinical study)
- Hürzeler MB1, Weng D. Int J Periodontics Restorative Dent. 1999 Jun;19(3):279-87. (clinical study)
- Pjetursson et al. J Clin Periodontol. 2008 Sep;35(8 Suppl):216-40. (clinical study)
- Tan et al. J Clin Periodontol. 2008 Sep;35(8 Suppl):241-54 (clinical study)
- Fan et al. Clin Implant Dent Relat Res. 2017 Feb;19(1):207-215. (clinical study)
- Thoma et al. J Clin Periodontol. 2015 Jan;42(1):72-80. (clinical study)
- Park et al. J Periodontal Implant Sci. 2016 Dec;46(6):415-425. (clinical study)
- Rothamel D et al. Clin. Oral Implants Res. 2005; 16(3): 369-378. (pre-clinical study)
- Perelman-Karmon M et al. Int J Periodontics Restorative Dent. 2012 Aug;32(4):459-65. (clinical study)
- Data on File. Geistlich Pharma AG, Wolhusen, Switzerland. (pre-clinical study)
- China market report suite for dental bone graft substitutes and other biomaterials, iDATA_CHDBGS18_MS, Published in November 2018 by iData Research Inc., 2018. (market research)
- Australia market report suite for dental bone graft substitutes and other biomaterials, iDATA_AUDBGS18_MS, Published in November 2018 by iData Research Inc., 2018. (market research)
- India market report suite for dental bone graft substitutes and other biomaterials, iDATA_IND-BGS18_MS, Published in November 2018 by iData Research Inc., 2018. (market research)
- South Korea market report suite for dental bone graft substitutes and other biomaterials, iDATA_SKDBGS18_MS, Published in November 2018 by iData Research Inc., 2018. (market research)
- Japan market report suite for dental bone graft substitutes and other biomaterials, iDATA_JPDBGS18_MS, Published in November 2018 by iData Research Inc., 2018. (market research)

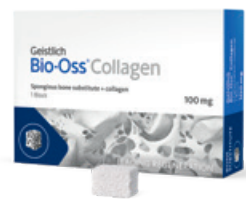Product Range*



Geistlich Bio-Oss®

Small granules (0.25–1 mm) | Quantities: 0.25 g, 0.5 g, 1.0 g, 2.0 g (1 g ~ 2.05 cm³)
Large granules (1–2 mm) | Quantities: 0.5 g, 1.0 g, 2.0 g (1 g ~ 3.13 cm³)

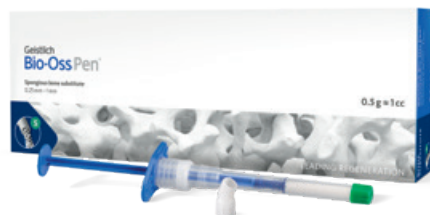The small Geistlich Bio-Oss® granules are recommended for smaller 1–2 socket defects and for contouring autogenous block grafts. The large Geistlich Bio-Oss® granules enable improved regeneration over large distances and provide enough space for the in-growing bone.



Geistlich Bio-Oss® Collagen

Geistlich Bio-Oss® (small granules) + 10% collagen (porcine)
Sizes: 50 mg (2.5 × 5.0 × 7.5 mm), 100 mg (5.0 × 5.0 × 7.0 mm),
250 mg (7.0 × 7.0 × 7.0 mm), 500 mg (10.0 × 10.0 × 7.0 mm)


Geistlich Bio-Oss® Collagen is indicated for use in periodontal defects and extraction sockets. Through the addition of collagen, Geistlich Bio-Oss® Collagen can be tailored to the morphology of the defect and is particularly easy to apply.



Geistlich Bio-Oss® Pen

Small granules (0.25–1 mm) | Quantities: 0.25 g ~ 0.5 cm³, 0.5 g ~ 1.0 cm³
Large granules (1–2 mm) | Quantity: 0.5 g ~ 1.5 cm³

Geistlich Bio-Oss® granules are available in an applicator. It allows the bone substitute material to be applied more precisely to the surgical site. Geistlich Bio-Oss® Pen is available with either the small granules or the large granules.



Geistlich Bio-Gide®

Sizes: 13 × 25 mm, 25 × 25 mm, 30 × 40 mm

Geistlich Bio-Gide® stabilizes the grafted area and protects bone particles from dislocation for optimal bone regeneration.³² The natural collagen structure allows homogeneous vascularization, supports tissue integration and wound stabilization.³¹ The combination of flexibility, good adhesion, and tear resistance contribute to easy handling, in turn saving time, and simplifying the surgical procedure.³³



Geistlich Bio-Gide® Compressed

Sizes: 13 × 25 mm, 20 × 30 mm

Geistlich Bio-Gide® Compressed is the product twin to Geistlich Bio-Gide® with firmer properties compared to its twin.²⁵ The natural collagen structure protects allows homogeneous vascularization, supports tissue integration and wound stabilization.³¹ Geistlich Bio-Gide® easier to cut and firmer in touch.³³

* Availability may vary from country to country



More details about our
distribution partners:
www.geistlich-biomaterials.com

Manufacturer

Geistlich Pharma AG
Business Unit Biomaterials
Bahnhofstrasse 40
6110 Wolhusen, Switzerland
Phone +41 41 492 55 55
Fax +41 41 492 56 39
www.geistlich-biomaterials.com

Affiliate Australia and New Zealand

Geistlich Pharma Australia
and New Zealand
The Zenith – Tower A
Level 19, Suite 19.01
821 Pacific Highway
NSW 2067 Chatswood, Australia
Phone +61 1800 776 326
Fax +61 1800 709 698
info@geistlich.com.au
www.geistlich.com.au

Affiliate Great Britain and Ireland

Geistlich Sons Limited
1st Floor, Thorley House
Bailey Lane
Manchester Airport
Manchester M90 4AB, Great Britain
Phone +44 161 490 2038
Fax +44 161 498 6988
info@geistlich.co.uk
www.geistlich.co.uk

Affiliate North America

Geistlich Pharma North America Inc.
202 Carnegie Center
Princeton, NJ 08540 USA
Phone toll-free +1 855 799 5500
info@geistlich-na.com
www.geistlich-na.com

Distribution Canada

HANSAméd Ltd.
2830 Argenta Road
Unit 5–8
L5N 8G4 Mississauga, Canada
Phone +1 800 363 2876
Fax +1 800 863 3213
orders@hansamed.net
www.hansamed.net



Geistlich Biomaterials – 100% regeneration expertise

- › Production of innovative bio-derived products for bone and soft-tissue regeneration.
- › From research, development and production to marketing: 100% regeneration expertise under one roof.
- › More than 165 years of experience in bone and collagen processing.
- › Close ties with the international dental and scientific community to find solutions to improve patient's quality of life.
- › Our pioneering regenerative dentistry products include the Geistlich Bio-Oss®, Geistlich Bio-Gide®, Geistlich Mucograft® and Geistlich Fibro-Gide® product families.